

Outcome of Ender's nailing in pediatric patient with Shaft of Femur Fracture in a Tertiary Care Hospital

Rahman Rasool Akhtar¹, Waqas Ali², Riaz Ahmed³, Muhammad Umair Qammar⁴, Omair Ashraf⁵,
Amna Iftikhar⁶

¹ Assistant Professor Orthopedic Surgery, Holy Family Hospital, Rawalpindi Medical University, Rawalpindi.

² Assistant Professor Orthopedic Surgery, CMH Kharian Medical College, Kharian.

³ Dean Ortho, N/S & Trauma, Professor of Orthopedic Surgery, Rawalpindi Medical University, Rawalpindi.

⁴ Senior Registrar Orthopaedics, Holy Family Hospital, Rawalpindi.

⁵ House Officer, Rawalpindi Medical University, Rawalpindi.

⁶ Final year MBBS Student, Rawalpindi Medical University, Rawalpindi.

Author's Contribution

^{1,2,3} Conception of study

^{1,2,3} Experimentation/Study conduction

^{1,2,4} Analysis/Interpretation/Discussion

^{1,4,5,6} Manuscript Writing

^{3,4} Critical Review

^{2,3,5,6} Facilitation and Material analysis

Corresponding Author

Dr. Rahman Rasool Akhtar,

Assistant Professor Orthopedic Surgery,

Holy Family Hospital,

Rawalpindi Medical University,

Rawalpindi

Email: virgo_r24@hotmail.com

Article Processing

Received: 20/08/2022

Accepted: 02/09/2022

Cite this Article: Akhtar, R.R., Ali, W., Ahmed, R., Qammar, M.U., Ashraf, O., Iftikhar, A. Outcome of Ender's nailing in pediatric patient with Shaft of Femur Fracture in a Tertiary Care Hospital. *Journal of Rawalpindi Medical College*. 30 Sep. 2022; 26(3): 509-513.

DOI: <https://doi.org/10.37939/jrmmc.v26i3.2007>

Conflict of Interest: Nil

Funding Source: Nil

Access Online:



Abstract

Introduction: The use of spica casting in children with the shaft of femur fractures is controversial. Presently, operative treatment is the main standard for the management of shaft of femur fractures in children. The advantages of Ender's nail are closed insertion of the nail with the preservation of fracture hematoma, minimal chances of infection and the endosteal blood supply is preserved because no reaming is required.

Objective: To determine the treatment outcome of Ender's nailing in the pediatric shaft of femur fractures in terms of limb length discrepancy, function, and union.

Materials and Methods: This descriptive study was conducted at Orthopaedic Department, Benazir Bhutto Hospital, Rawalpindi Medical University, Rawalpindi from January 2017 to December 2019. We enrolled 95 children 6-12 years of age by using a non-probability consecutive sampling technique with femoral shaft fracture. The exclusion criteria include children with pathological fractures, malignancy, and skeletal dysplasia. Time of surgery, implant failure, infection, union, limb length discrepancy, and functional outcome were recorded. Functional outcome and union were determined by using Flynn criteria and radiographs while the surgery time, infection, limb length discrepancy, and implant failure were determined clinically.

Results: There were 59 (62.1%) male and 36 (37.89%) female children. The mean age was 6.93 ± 4.12 years. The mean surgery duration was 30 ± 8.5 minutes. There were 06 (6.31%) superficial and no patients with deep infection. No implant failure in our study. The time duration from radiological & clinical union to full weight bearing was 7.9 weeks (5-12 weeks). On Flynn criteria, 67 (70.52%) children had excellent and 28 (29.47%) had a satisfactory functional outcomes. In 85 (89.47%) children, there was no limb length discrepancy but 10 (10.5%) children had limb length discrepancy with a mean of 5.45 ± 1.23 mm.

Conclusion: Ender's nailing is an excellent treatment option for the pediatric shaft of femur fractures in terms of functional outcome and union with low chances of infection, limb length discrepancy, and implant failure.

Keywords: Ender's nailing, pediatric femoral shaft fracture, union, functional outcome, infection, implant failure, limb length discrepancy.

Introduction

Femoral shaft fractures are frequent orthopaedic injuries that can arise from either low or high-energy trauma in older patients. A complete trauma life support assessment and interdisciplinary care are required since comorbidities usually accompany femoral shaft fractures. Intramedullary nailing is the gold standard among the various treatment techniques, producing exceptional results. Early union and prolonged functional recovery are the main objectives of fixation.¹ Between 10 and 21 femoral shaft fractures in every 100,000 people occur each year globally. Open fractures contribute to 2% of these fractures.² According to the American Society for Bone and Mineral Research (ASBMR) Task Force 2013, atypical fractures of the femur range from 3.5 percent to 16 percent.³

Operative or non-operative treatment options are available for femoral shaft fractures. In developed countries, the gold standard of treatment is intramedullary nailing during surgical fixation. External fixation and plate osteosynthesis are further surgical methods. In some third-world nations, closed management including splinting, traction, and hip spica casting is the temporary or permanent solution.⁴ The key issues include osteoporosis, geriatric age-related medical issues, and anesthetic risk complications. Long operating times, wide exposure, muscle damage, blood loss, increased infection rates, increased post-operative pain, the need for blood transfusions, delayed morbidity, as well as major surgery to remove the implant in the event of failure or union are the main drawbacks of fixation methods other than ender's nail.⁵

Ender's nailing was extremely popular in the past, but with the development of new implants, it became a lost art. Even though it has several benefits, including a quick recovery time, less blood loss, lowered infection risk, decreased nonunion, and low cost. Knee discomfort and stiffness as well as nail migration or shortening of the limb, particularly in unstable varieties, are major problems with Ender's nailing. With the approach adopted, external rotation is not a big issue. It produces great results with minimal invasion in stable fractures. Focusing on the Ender nailing technique and choosing the right patient is crucial for the success of this implant at the lowest possible cost.⁶ Ender's nailing technique, when properly applied, can be completed in a very short time without any blood loss, major post-operative infection, or need for blood transfusion. It is also

minimally invasive which reduces post-operative pain. Due to superior biomechanics, there is also less risk of implant breaking and non-union and it is very simple and inexpensive to have the implant removed while sedated. The drawbacks include knee discomfort and stiffness, nail migration both proximally and distally, supracondylar fracture at the site of insertion, rotational deformity, and limb shortening.⁶ Ender's nail offers a straightforward, affordable treatment for these fractures with high union rates and few side effects.⁷ Ender's nailing is a promising therapeutic option for children with the shaft of femur fractures when there is a length discrepancy. In 5.5% of cases, leg discrepancy might arise.⁸

Complications after surgical management of femoral shaft fracture are high and most patients develop discrepancies. But limited work has been done before regarding Ender nail in femoral shaft fracture. In a poor resource country including Pakistan, it is important to lessen the postoperative complications to reduce the cost of surgery for patients as well as for hospital administration. Therefore, we conduct this study to get evidence for the management of femoral shaft fracture by using Ender's nailing. This would help us to get local evidence and in the future, we will implement the Ender nails for such fractures in order to improve our practice and achieve more success and fewer complications.

Objective: To determine the treatment outcome of Ender's nailing in pediatric shaft of femur fractures in terms of limb length discrepancy, function, and union.

Materials and Methods

Study design: Descriptive study.

Setting: Department of Orthopaedics, Benazir Bhutto Hospital, Rawalpindi Medical University, Rawalpindi.

Study duration: About 03 years i.e., January 2017 to December 2019.

Sample size: A sample size of 95 cases was estimated by using a 95% confidence level, 5% margin of error, and percentage of limb discrepancy i.e., 5.5% with Ender's nail in femoral shaft fracture.

Sampling technique: Non-probability, consecutive sampling.

Selection criteria: Children of age 6 - 12 years, both genders, with fracture shaft of femur were enrolled. Patients with recurrent fractures at the same site already had implants and who presented with implant failure, skeletal dysplasia, malignancy, or pathological fractures were not included in the study.

Data collection method: Patients fulfilling above stated selection criteria were enrolled from emergency and OPD. Informed written consent was obtained. Demographics like name, age, gender, BMI, duration between fracture and presentation in the hospital, and cause of fracture were obtained. Then patients underwent internal fixation with Ender's nail by Consultant Orthopedic Surgeon and his surgical team under general anesthesia. The duration of surgery was noted. After surgery, children were shifted to post-operative wards and were monitored there till discharge. For at least one week after surgery, patients have been advised a standard antibiotic regimen along with standard medical treatment. The total hospital stay was noted. During the first 7-10 days, patients were evaluated for infection. Patients were followed-up in OPD for about 6-12 months on monthly basis. On each visit, an x-ray was performed to determine the callus formation to determine union. After 6 months, limb discrepancy was noticed against the normal parallel leg. Patients were also evaluated on Flynn's criteria to determine the functional outcome at 06 months. All the data was collected in a proforma, specially designed for this research.

Analysis plan: All the collected information was entered and analyzed by using SPSS v. 25. Infection, implant failure, functional outcome, and the union was presented as frequency and percentage while outcome like operative time and hospital stay was presented as mean and standard deviation.

Results

The mean age of children was 6.93 ± 4.12 years in our study. There were 59 (62.1%) male and 36 (37.89%) female children. The mean duration of fracture was 2.32 ± 1.07 days. The main cause of fracture was a road traffic accident [41 (43.1%)], followed by a fall from height [30 (31.57%)], a fight with someone [17 (17.89%)] and being hit with a hard surface [7 (7.36%)]. (Table 1)

The mean surgery duration was 30 ± 8.5 minutes. The mean duration of hospital stay was 5.4 ± 1.4 days after surgery. The mean time duration from clinical & radiographic union to full weight bearing was 7.9 ± 1.75 weeks (5-12 weeks). Out of 95 cases, wound infection was noticed in 6 (6.31%) cases and all those patients had superficial wound infection and no patient developed deep wound infection. On Flynn criteria, 67 (70.52%) children had excellent and 28 (29.47%) had satisfactory functional outcomes and there was no implant failure. The limb length

discrepancy was observed in 10 (10.5%) cases while 85 (89.47%) children showed equal length as compared to the parallel leg. The mean discrepancy was observed as 5.45 ± 1.23 mm in 10 (10.5%) children. (Table 2)

One case was presented in the preoperative period till 8 weeks of follow-up showing a union of bone. (Figure 1)

Table 1: Baseline features of patients

Feature	Mean \pm SD, F (%)
n	95
Age (in years)	6.93 ± 4.12
Gender	
Male	59 (62.1%)
Female	36 (37.89%)
Duration of fracture (days)	2.32 ± 1.07
Cause of fracture	
Road traffic accident	41 (43.1%)
Fall from height	30 (31.57%)
Fight/beaten by someone	17 (17.89%)
Hit something hard	7 (7.36%)

Table 2: Outcome of patients after surgery

Outcome	F (%), mean \pm SD
Duration of surgery (in minutes)	30.0 ± 8.5
Duration of hospital stay (days)	5.4 ± 1.4
Duration of full weight bearing (weeks)	7.9 ± 1.75
Complications	
Wound infection	6 (6.31%)
Superficial wound infection	6 (6.31%)
Deep wound infection	0 (0.0%)
Flynn criteria	
Excellent	67 (70.52%)
Satisfactory	28 (29.47%)
Implant failure	0 (0.0%)
Limb discrepancy	10 (10.5%)
Mean discrepancy (in mm)	5.45 ± 1.23

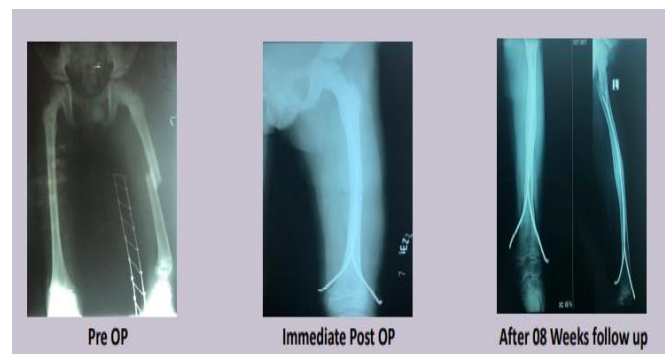


Figure 1: Preoperative and postoperative x-ray findings

Discussion

Instead of focusing solely on the union of the fracture, fracture treatment now aims to maximize limb function as quickly as possible. For the treatment of intertrochanteric fractures, a number of therapy procedures have been reported, each with advantages and disadvantages. These ranges from conservative maintenance to various surgical procedures using various implants.⁹ With the use of flexible nails, displaced tibial shaft fractures in children can be successfully treated with few side effects.⁷

Nevertheless, the sole instrument that many orthopaedic surgeons continue to employ, especially in older children, is Ender's nail. The convenience of the treatment, the reduction in operative time, and the reduction in blood loss with early mobilisation are benefits of employing Ender's nailing over other implants.^{10,11} Depending on the prevalence of polytrauma, neurovascular injury, or accompanying ipsilateral limb fractures, casting or Ender's nailing can be used to treat displaced tibial shaft fractures in younger children. Flexible nailing is thought to be minimally invasive and safe. According to Stenroos et al., non-operative treatment resulted in a 24 percent loss of alignment (5° - 15° varus or recurvatum), compared to flexible nail treatment, which only caused a 2 percent loss of alignment.¹²

In the past, intramedullary Ender nailing for intertrochanteric fractures was fairly common. However, because of its drawbacks, this approach has lost popularity over time.¹³ Nearly 12,000 cases in Europe have involved the use of Ender's nails; in contrast, the method is less common in North America. Despite their benefits, Ender's nails have poor rotational stability.¹³

In our study, we enrolled 95 children with femoral shaft fractures and performed Ender's nailing. We observed the mean surgery duration was 30 ± 8.5 minutes. The mean duration of hospital stay was 5.4 ± 1.4 days after surgery. The mean duration of time from radiological & clinical union to full weight bearing was 7.9 ± 1.75 weeks (5-12 weeks). Out of 95 cases, wound infection was noticed in 6 (6.31%) cases and all those patients had superficial wound infection and no patient developed deep wound infection. On Flynn criteria, 67 (70.52%) had excellent and 28 (29.47%) had satisfactory functional outcomes and there was no implant failure in our study. The limb length discrepancy was observed in 10 (10.5%) cases while 85 (89.47%) children showed equal length as compared to

the parallel leg. The mean discrepancy was observed as 5.45 ± 1.23 mm in 10 (10.5%) children.

In their investigation, Park et al. noted that the average time of operation was 65.00 ± 22.64 minutes. No patient developed an entirely unusual fracture. The confirmation of endocortical callus formation, the elimination of the fracture line, and the union of bone clinically took 2.11 ± 0.53 months, 6.45 ± 4.10 months, and 6.45 3.65 months, respectively.¹⁴

According to Herscovici et al., using Ender nails to manage femoral shaft fractures is technically simpler and takes less time than using the current intramedullary nailing methods. With Ender nailing, they treated twenty-six stable and seventeen unstable fractures. 42 percent of the stable fractures group and 76 percent of the unstable fractures group needed additional stabilization in the form of skeletal traction, an external fixator, or a cast due to ongoing instability. In addition, fourteen fractures in each group had nail migration, shortening, and loss of knee mobility. Although 2/3rd of patients in the stable fractures group had good or excellent outcomes, only 19% of the outcomes in the unstable group were assessed as good or excellent. Therefore, they advised using of intramedullary interlock nails in diaphyseal fractures of the femur. As a result, only stable fracture patterns that can be secured with screws or wires should employ Ender's nails. They may be especially helpful for young children with fractures that require intramedullary stabilization without damaging the growth plates and femoral fractures with narrow medullary canals (less than or equal to 8 mm).¹⁵

In order to assess the length difference following Ender's nail fixation in the pediatric shaft of femur fractures, Kwon et al. conducted a study. They looked at 18 shafts of femur fractures that were managed with Ender's nails and investigated the connection between the fracture's initial site, kind, and outgrowth. Children of age range from 6 to 12 years and the average time of follow-up was 32 months. Leg length difference ranged from 6 mm shortening to 16 mm lengthening, with an average lengthening of 3.4 mm. Eight individuals experienced lengthening, nine had limbs that were equal in length (less than 2 mm), and only one patient had shortened. The average overgrowth was 3.0 mm in distal 1/3 fractures, 1.3 mm in the middle 1/3, and 7.0 mm in the proximal third. The average outgrowth in transverse, oblique, and comminuted fractures was 7.3 mm, 1.3 mm, and 2.3 mm, respectively. In the case of leg length difference, they thought that closed Ender nailing was a

promising therapeutic option for children with femoral shaft fractures.¹⁶

Conclusion

Ender's nailing is an excellent treatment option for the pediatric shaft of femur fractures in terms of functional outcome and union with low chances of infection, limb length discrepancy, and implant failure. So, in the future, we will recommend this method for such types of fractures to achieve >90% success (i.e., good to an excellent functional outcome) with the maximum number of unions.

References

- Denisiuk M, Afsari A. Femoral Shaft Fractures. StatPearls. Treasure Island (FL): StatPearls Publishing Copyright © 2022, StatPearls Publishing LLC.; 2022.
- Enninghorst N, McDougall D, Evans JA, Sisak K, Balogh ZJ. Population-based epidemiology of femur shaft fractures. *J Trauma Acute Care Surg.* 2013;74(6):1516-20. DOI: 10.1097/TA.0b013e31828c3dc9.
- Saita Y, Ishijima M, Kaneko K. Atypical femoral fractures and bisphosphonate use: current evidence and clinical implications. *Therap Adv Chronic Dis.* 2015;6(4):185-93. DOI: 10.1177/2040622315584114.
- Hussain N, Hussain FN, Sermer C, Kamdar H, Schemitsch EH, Sternheim A, et al. Antegrade versus retrograde nailing techniques and trochanteric versus piriformis intramedullary nailing entry points for femoral shaft fractures: a systematic review and meta-analysis. *Can J Surg.* 2017;60(1):19-29. DOI: 10.1503/cjs.000616.
- Patil NS, Sharma V. Ender's nailing in inter trochanteric fracture. *Int J Orthop Sci.* 2019;5(2):182-6. DOI: 10.22271/ortho.2019.v5.i2d.34.
- Lakhnotra PH, Vania MB. Ender's nailing in inter trochanteric femur fracture: A retrospective analysis of 50 cases. *Int J Orthop Sci.* 2020;6(1):45-9. DOI: 10.22271/ortho.2020.v6.i1a.1832
- Durga Prasad V, Sangeet G, Venkatadass K, Rajasekaran S. Ender's nailing of displaced tibia shaft fractures in children - A nine-year experience. *Injury.* 2021;52(4):837-43. DOI: 10.1016/j.injury.2020.10.032.
- Matsumura T, Saito T, Watanabe H, Kikkawa I, Takeshita K. Legg-Calvé-Perthes disease following Ender nail fixation of a pediatric femoral fracture. *Int J Surg Case Rep.* 2021;85:106209. DOI: 10.1016/j.ijscr.2021.106209.
- Gandhi S, Solanki RA. Results of ender's nailing in intertrochanteric fractures femur. *Indian J Orthop Sci.* 2022;8(1):42-5. DOI: 10.22271/ortho.2022.v8.i1a.2989
- Gill JB, Jensen L, Chin PC, Rafiei P, Reddy K, Schutt RC, Jr. Intertrochanteric hip fractures treated with the trochanteric fixation nail and sliding hip screw. *J Surg Orthop Adv.* 2007;16(2):62-6.
- Shaha J, Cage JM, Black S, Wimberly RL, Shaha SH, Riccio AI. Flexible Intramedullary Nails for Femur Fractures in Pediatric Patients Heavier Than 100 Pounds. *J Pediatr Orthop.* 2018;38(2):88-93. DOI: 10.1097/BPO.0000000000000775.
- Stenroos A, Puhakka J, Nietosvaara Y, Kosola J. Treatment of Closed Tibia Shaft Fractures in Children: A Systematic Review and Meta-Analysis. *Eur J Pediatr Surg.* 2020;30(6):483-9. DOI: 10.1055/s-0039-1693991.
- Ertürk C, Çağman B, Altay MA, Işkan UE. The use of Ender nail in intertrochanteric fractures supported with external fixation. *Turk J Trauma Emerg Surg.* 2011;17(5):407-12.
- Park JH, Cho YJ, Chun Y-S, Rhyu KH. A Novel Surgical Method for Treating Symptomatic Incomplete Atypical Femoral Fracture using Percutaneous Elastic Intramedullary Nailing. *Geriatr Orthop Surg Rehab.* 2021;12:21514593211015104. DOI: 10.1177/21514593211015104.
- Herscovici D, Jr., Scott DM, Behrens F, Nelson B, Benton J. The use of Ender nails in femoral shaft fractures: what are the remaining indications? *J Orthop Trauma.* 1992;6(3):314-7. DOI: 10.1097/00005131-199209000-00008.
- Kwon JW, Shin SH, Cho WH, Lee WS, Park JH. Leg Length discrepancy after ender nail fixation in children femoral shaft fracture. *J Korean Soc Fract.* 2000;13(1):172-7. DOI: 10.12671/jksf.2000.13.1.172