

# Outcome of Langerhans Cell Histiocytosis Among Children

Alia Ahmad<sup>1</sup>, Sobia Akram<sup>1</sup>, Ahmed Imran<sup>2</sup>, Fauzia Shafi Khan<sup>1</sup>, Carlos Rodriguez-Galindo<sup>3</sup>

Department of Paediatric Haematology /Oncology, Children Hospital, Lahore;<sup>2</sup> Department of Radiology , Children Hospital, Lahore;<sup>3</sup>. St. Jude Children's Research Hospital Memphis TN, USA

## Abstract

**Background:** To analyze the spectrum of challenges faced in the treatment of Langerhen Cell Histiocytosis resource limited settings lacking salvage therapy.

**Methods:** In this observational study , 42 patients of Langerhans cell histiocytosis were enrolled. Risk organ involvement, treatment course and outcome were analyzed. The patients were treated with vinblastine and prednisolone as first line given weekly for 6 weeks and then 3-weekly as a continuation therapy up to 6-12 months. Doses were calculated according to body surface area. Intravenous Cytarabine pulses used for 5 days 3-weekly apart and Japanese Protocol used for refractory cases. The salvage therapy available in developed countries in the form of 2-CdA (2-chlorodeoxyadenosine) and RIC -SCT reduced-intensity conditioning stem cell transplantation not available in our center. In our study Group A include patients who refused enucleation and opted out of recommended treatment plan and Group B patients had enucleations done and followed treatment plans.

**Results:** Age of the patients range from < 1 to 10 years (19% <2 yrs). M: F Ratio was 2:1. Majority (72%) of the patients presented with multisystem-LCH (MS-LCH) with 100% mortality in MS-LCH group (p-value=0.045) and 18/42 (43%) had risk organ involvement with 72% mortality. Twenty nine (70%) had bone lesions and 12(29%) had central nervous system involvement. Fifty five percent completed treatment, 2/42 (5%) are on treatment, 9/42 (21%) abandoned treatment and 8/42 (19%) expired due to progressive disease and worsening infection. Sixteen (38%) had reactivations of disease requiring therapy for more than one year. Twenty four percent of cases received two cycles of initiation therapy before continuation therapy started. The treatment initiated >6 months after the onset of symptoms in 30/42 (72%) of cases with 100% expiries in this group and 89% of abandonment. The children presenting at younger age had risk of having MS-LCH 75% as compared to 36% in age >2years.

**Conclusion:** Treatment abandonment, delayed diagnosis and poor social support are major

challenges in treating LCH in developing countries. Early diagnosis and timely treatment with effective infection control measures and strong social support are of utmost importance to improve long term overall survival.

**Key Words:** Langerhans Cell Histiocytosis, Multiorgan , Chemotherapy

## Introduction

Langerhans Cell Histiocytosis (LCH) is a relatively rare disease accounting for < 2% of new cases each year enrolled in The Children's Hospital Lahore. LCH previously termed as histiocytosis X occurs primarily in childhood and is a rare clonal disorder of Langerhans cell proliferation, the antigen presenting immature dendritic cells that originate in bone marrow.<sup>1</sup> The clinical manifestations vary widely from a self limiting unifocal bone lesion to a multi-system disease including rapidly fatal organ dysfunction. Currently LCH is classified as single-system (SS) and multisystem (MS) disease again divided in two groups depending on risk organ (RO), namely, liver, spleen and bone marrow involvement, RO-negative MS and RO-positive MS disease.<sup>2,3</sup> The incidence of LCH is 4-5 cases per million per year in children less than 15 years with peak at less than 3 years of age. It is more common in boys than girls (1.2-2:1). LCH is usually sporadic though genetic predisposition may play a role as it is reported in twins and 1% of patients have relatives with LCH.<sup>4</sup>

For LCH diagnosis, histopathological examination is essential with histiocytes positive for CD1a or Langerin (CD207) on immunohistochemistry. Langerin is a cell surface receptor that triggers the formation of the Birbeck granules which are Langerhans cell-specific tennis racquet-shaped organelle detected by electron microscopy. Active LCH lesions contain LCH cells aggregates forming granulomas along with several inflammatory cells predominantly macrophages in later stages. When CD1a-positive cells show dysmorphic features and mitotic figures , Langerhans cell sarcoma should be excluded.<sup>5,6</sup> The etiology of LCH has been debatable whether it is reactive based on the fact that these lesions sometimes show spontaneous regression and some virus DNA sequences have been found in blood and tissues of

LCH patients.<sup>7,8</sup> However, many facts support it as a neoplasm such as LCH cells are monoclonal and they also sometimes depict chromosomal deletion or gain more than 50% LCH patients, oncogenic BRAF V600E mutations are found associated with higher reactivation rate[11] though present in equal frequency in SS and MS LCH.<sup>9-12</sup> Treatment course of LCH is quite variable depending on the extent and risk organ involvement. The mortality is less in SS LCH or without risk organ involvement is <5% and upto 10-50% in MS LCH and RO positive disease.<sup>13</sup>

### Patients and Methods

In this observational study, conducted at the department of Paediatric Haematology/Oncology of the Children’s Hospital & the Institute of Child Health Lahore, 42 patients of Langerhans Cell histiocytosis were enrolled, from January 2011 to December 2015. Data regarding their age, sex, classification, Risk organ involvement, treatment course and outcome analyzed. The patients were treated with vinblastine and prednisolone as first line given weekly for 6 weeks and then 3-weekly as a continuation therapy up to 6-12 months. Doses calculated according to body surface area. Intravenous Cytarabine pulses used for 5 days 3-weekly apart and Japanese Protocol used for refractory cases. The salvage therapy available in developed countries in the form of 2-CdA (2-chlorodeoxyadenosine) and RIC -SCT reduced-intensity conditioning stem cell transplantation not available in our center. In our study Group A included patients who refused enucleation and opted out of recommended treatment plan and Group B patients had enucleations done and followed treatment plans.

### Results

Total 42 patients with age ranging from < 1 to 10 years (19% <2 yrs) were included. M: F Ratio was 2:1. Majority (72%) patients presented with multisystem-LCH (MS-LCH) with 100% mortality in MS-LCH group (p-value=0.045) (Group A). Eighteen out of forty two (43%) had Risk Organ involvement with 63% mortality (Group B). The treatment initiated >6 months after the onset of symptoms in 30/42 (72%) (Group C) of cases with 100% expiries in this group and 89% of abandonment (Table 1). Children presenting at younger age had risk of having Risk Organ involvement 75% as compared to 36% in age >2 years (Table 2). Majority (70%) of patients had bone lesions. While 12/42 (29%) had central nervous system (CNS) involvement. Sixteen patients (38%) had reactivations of disease requiring therapy for more

than one year. 24% of cases received two cycles of initiation therapy before continuation therapy started. Twenty three (55%) completed treatment, 2/42 (5%) are on treatment, 9/42 (21%) abandoned treatment and 8/42 (19%) expired due to progressive disease and worsening infection (Table: 3).

**Table 1: Outcome of High Risk Group**

Group A	MS-LCH (Multisystem)	Expired: 8/8 LAMA*: 6/9	100% 67%	p-value 0.380
Group B	RO+ (Risk Organ+)	Expired: 5/8 LAMA: 7/9	62% 78%	p-value 0.020
Group C	Time Lag >6 months	Expired: 8/8 LAMA: 8/9	100% 89%	p-value 0.029

\*Left against medical advice

**Table 2 Age Presentation**

Group A: <2 Years: 8	MS-LCH: 7/8 88% SS-LCH: 1/8	RO+: 6/8 75% RO-: 2/8
Group B: >2 Years: 34	MS-LCH: 23/34 68% SS-LCH: 11/34	RO+: 12/34 36% RO-: 22
		p-value: 0.041

**Table 3: Langerhan Cell Histiocytosis - Treatment Outcomes (n=42)**

Parameter	No	%
Treatment completed	23	55
On treatment	2	05
LAMA	9	21
Expired at home	3	07
Expired in hospital	5	12

### Discussion

LCH can involve any organ or system with clinical manifestations in skin, CNS, bone, lung, liver, lymph nodes and haematological system with wide differential diagnoses confirmed by histological and immunophenotypic examination of the lesions in the form of positive CD1a and or CD207 (Langerin) for a definitive diagnosis.<sup>14</sup> If the risk of biopsy is more than the need of definitive diagnosis, then effort should be made to exclude other conditions with similar radiological features and should be on close follow up.<sup>15</sup> In our study 72% cases had their symptoms for more than six months before their diagnosis of LCH was made and definitive treatment started. The combination of Vinblastine and prednisolone is being used in LCH since 1966 and alone or with other chemotherapeutic agents these have been used in different prospective trials in MS-LCH in over 1000

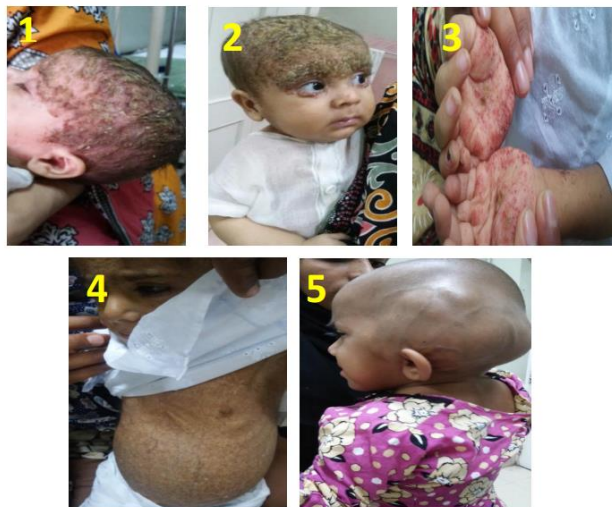

Fig 1-4: Skin manifestations on scalp, palms and abdomen; Fig 5: CNS-Risk Lesion on Parieto-Occipital Region

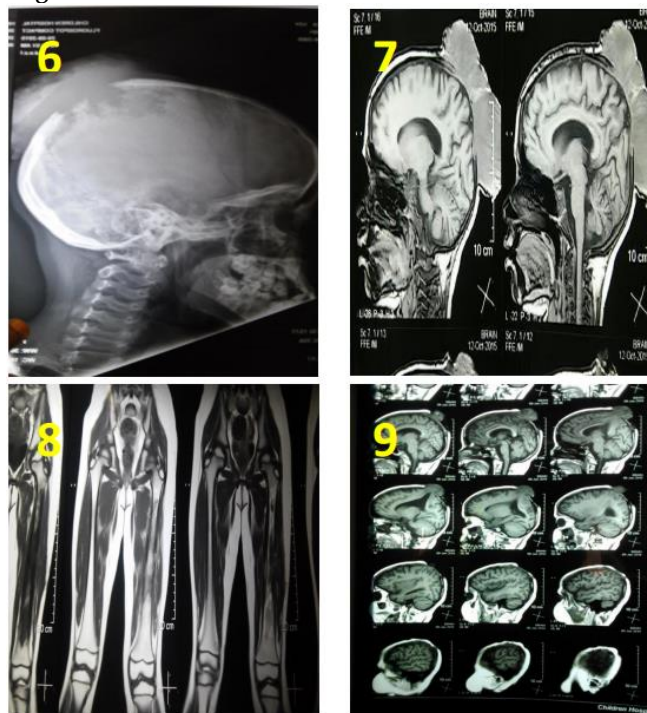


Fig 6: X-ray Skull Lateral view demonstrates bizarre ill-defined lucencies involving upper parietal region; Fig 7: MRI sagittal T1W image demonstrates isointense soft tissue mass at Parieto-occipital region; Fig 8: MRI lower limb T1W images showing heterogeneous signal intensities in left femoral diaphysis; Fig 9: T1W sagittal MRI brain images demonstrate a soft tissue intensity lesion at vertex of the scalp with disrupted diploae spaces

patients with excellent tolerability with overall success of at least 60%.<sup>16</sup> Therefore this combination can be used effectively in resource limited settings with success as it is cost effective and well tolerated as

evidenced by LCH-III trials with 70% and 86% initial response in RO+ and RO- MS-LCH patients.<sup>17</sup> In LCH-IV, a large prospective trial, one of the focuses is to evaluate the role of second-line chemotherapeutic agents including cytarabine which minimize reactivations and permanent sequelae of LCH, a protocol which induces complete response and effective in neurodegenerative CNS-LCH.

In refractory cases in risk -organ involvement it is suggested to be treated in specialized centers with a combination of cladribine (2-CdA and cytarabine (Ara-C) and in non-risk organ cases 2-CdA can be used as a monotherapy or further courses of standard vinblastine and prednisolone combination, but 2CdA and RIC-SCT is not available in our center so few cases expired due to progression of disease not responded to standard therapy.<sup>18-20</sup>

LCH can be cured with standard chemotherapy in low income countries as described in Guatemala, El Salvador, Honduras, and Nicaragua with 57% well in remission, 16% on treatment, 24% abandonment and 3% expiries as compared to our study showing 21% abandonment and 19% expiries due to progressive disease, advanced stages and superimposed infections. So the focus should be on minimizing the abandonment in LCH patients in low income countries.<sup>21</sup>

Reactivation is common in MS-LCH up to 50% cases with spontaneous recovery in some and requiring treatment in others with resolution. This reactivation is more common in first two years of disease onset and bone is more frequently involved than risk organs. It results in permanent sequelae also requiring close follow up and monitoring.<sup>22,23</sup> In our study 38% of cases had reactivation of LCH and 62% among MS-LCH requiring further treatment. These children need follow up and monitoring of permanent sequelae of different tissues like endocrinopathy (Diabetes Insipidus, Growth hormone deficiency, pubertal delay), orthopedic complications like scoliosis, hearing deficits requiring hearing aids, neuropsychological impairment (cerebellar ataxia, learning difficulties) and associated malignancies.<sup>24</sup> These facilities are available in our center so these children are encouraged for long follow up and monitoring.

## Conclusion

1. Delayed diagnosis, treatment abandonment and poor social support are major challenges in treating LCH in developing countries. 2. Early diagnosis and timely treatment with effective infection control measures and strong social support are of

utmost importance to improve long term overall survival of these children being treated with standard chemotherapy.

## References

1. Jon D, Laman JD , Pieter JM, Nicola E, Pancras CW. Langerhans cell Histiocytosis 'Insight into DC biology. Trends Immunol.2003; 24:190-96.
2. Morimoto A, Yukiko OH, Shiote Y. Recent Advances in Langerhans Cell Histiocytosis. Pediatrics International 2014; 56: 451-61
3. French Langerhans cell histiocytosis Study group, A multicenter retrospective survey of Langerhans cell histiocytosis: 384 cases observed between 1983 to 1993. Arch Dis Child 1996; 75: 17-24.
4. Aricò, M and Danesino C. Langerhans' cell histiocytosis: is there a role for genetics? Haematologica-Pavia then Roma 2001; 86(10): 1009-14.
5. Jaffe R and Weiss LM. Tumors derived from Langerhans cells. In: Swerdlow SH, Campo E, Harris NL et al.(eds) WHO Classification of Tumors, Tumors of Haematopoietic and Lymphoid Tissues, 4<sup>th</sup> Edn. IARC, Lyon, 2008; 358-60.
6. Lau S K, Chu PG, Weiss LM. Immunohistochemical expression of Langerin in Langerhans cell histiocytosis and non-Langerhans cell histiocytic disorders.The American journal of surgical pathology.2008; 32(4): 615-19.
7. Minkov M, Prosch H. Langerhans cell histiocytosis in neonates. Pediatr. Blood Cancer 2005; 45:802-07
8. Murakami I, Matsushita M, Prosch H, Steiner M, Grios N. Merkel cell polyoma virus DNA sequence in peripheral blood and tissues from patients of Langerhans cell Histiocytosis. Hum. Pathol.2014; 45: 119-26.
9. Willman CL, Busque L Griffith BB. Langerhans Cell histiocytosis- a clonal proliferative disease. N. Engl. J. Med. 1994; 331: 154-60
10. Murakami I, Gogusev J, Formert JC, Glorion C. Detection of molecular cytogenetic aberrations in Langerhans cell Histiocytosis of bone. Hum. Pathol.2002; 33: 555-60
11. Satoh T, Smith A , Sarde A, Lu H, Mian S. B-RAF mutant alleles associated with Langerhans cell histiocytosis, a Granulomatous pediatric disease. PLoS ONE 2012; 7: e33891
12. Berres ML, Lim KP, Peter T, Price J. BRAF-V600E expression in precursor versus differentiated dendritic cells defines clinically distinct LCH risk groups. J. Exp. Med. 2014; 211: 669-83.
13. Donadieu J, Egeler RM, Beller S, Thomas C. Langerhans cell histiocytosis: a clinical update In: Weitzman S, Egeler RM (eds). Histiocytic disorders of children and adults. Cambridge University Press, Cambridge, 2005: 95-129
14. Swerdlow SH and Campo E . WHO Classification of Tumors of Haematopoietic and Lymphoid tissues, 4<sup>th</sup> edition. Lyon: IARC press; 2008.
15. Haupt R, Minkov M, Astigaraga I. Langerhans Cell Histiocytosis: Guidelines for Diagnosis, Clinical work-up, and Treatment for patients till the Age of 18 Years. Pediatr Blood Cancer 2013;60: 175-84
16. Lahey ME, Histiocytosis X. An analysis of prognostic factors. J Pediatr 1975; 87: 184-89
17. Minkov M and Rodriguez- Galindo C. Treatment of Langerhans cell histiocytosis: It is time to learn from the past. British Journal of Haematology 2015; 171: 137-51
18. Bernard F, Thomas C, Bertrand Y, Munzer M. Multi-center pilot study of 2-chlorodeoxyadenosine and cytosine arabinoside combined chemotherapy in refractory Langerhans cell histiocytosis with haematological dysfunction. Eur J Cancer 2005; 41: 2682-89.
19. Steiner M, Matthes-Martin S, Attarbaschi A. Improved outcome of treatment-resistant high-risk Langerhans cell histiocytosis after allogeneic stem cell transplantation with reduced-intensity Conditioning. Bone Marrow Transplant 2005; 36: 215-25.
20. Weitzman S, Braier J, Donadieu J. 2-chlorodeoxyadenosine (2-CdA) as salvage therapy for Langerhans cell histiocytosis (LCH). Results of the LCH-S-98 protocol of the Histiocyte Society. Pediatr Blood cancer 2009; 53: 1271-76.
21. Gardner H, Grois N, Arico M, Broadbent V, Ceri A.. A randomized trial of treatment for Multisystem Langerhans cell histiocytosis. J Pediatr 2001; 138: 728-34.
22. Minkov M, Steiner M, Potschger U, Arico M. Reactivations in Multisystem Langerhans cell histiocytosis: data of the international LCH registry. J Pediatr. 2008;153: 700-05.
23. Morimoto A, Kobayashi R, Maeda M. Impact of reactivation on the sequelae of multisystem Langerhans cell histiocytosis patients. Pediatr. Blood cancer 2008; 50: 931-32
24. Haupt R, Minkov M , Astigrraga I. Langerhans Cell Histiocytosis: Guidelines for Diagnosis, Clinical work-up, and Treatment for patients till the Age of 18 Years. Pediatr Blood Cancer 2013; 60: 175-84.