

# Diagnosis of Polycystic Ovarian Syndrome on Doppler Based Resistive Index and Pulsatility Index

Asma Bano<sup>1</sup>, Asma Tariq<sup>2</sup>, Atiq-Ur-Rehman<sup>3</sup>

1. Department of Radiology, Shalmar Hospital, Lahore; 2, Department of Radiology, CMH, Lahore; 3. Armed Forces Institute of Radiology, Rawalpindi

## Abstract

**Background:** To determine Doppler based mean Pulsatility index and mean Resistive index in patient diagnosed with polycystic ovary syndrome.

**Methods:** In this cross sectional study one hundred and twenty patients with clinical diagnosis of polycystic Ovary Syndrome, who underwent through color transabdominal Doppler USG to determine the Pulsatility index and Resistive index of both uterine arteries were included. Each sonographic examination included bilateral study of uterine artery and then calculations of variables PI and RI and adding to get their mean

**Results:** The mean pulsatility index and resistive index of 120 patients (including both right and left uterine arteries) was  $3.89 \pm 0.76$  and  $0.93 \pm 0.10$ . Color Doppler scan correctly diagnosed cases in 84.2% patients.

**Conclusion:** Color Doppler pelvic scan can correctly diagnose the cases of PCOS in majority of the patients. The mean PI was high and lower RI of uterine artery was observed in our study

**Key Words:** Color Doppler transabdominal ultrasonography; Pulsatility index; resistive index, polycystic ovaries.

## Introduction

Polycystic ovarian syndrome (PCOS) is a common endocrine disorder of premenopausal women in their reproductive years.<sup>1</sup> It is a complex metabolic, endocrine and reproductive disorder affecting approximately 5-10% of the female population in developed countries.<sup>2</sup> The major features of polycystic ovarian syndrome (PCOS) include menstrual dysfunction, anovulation, and signs of hyperandrogenism.<sup>3</sup> PCOS can result from abnormal function of the hypothalamic-pituitary-ovarian (HPO) axis. It has also associated with raised biochemical marker of plasma testosterone level.<sup>4</sup>

Stein and Leventhal were the first to recognize this association.<sup>5</sup> Between 5-10% of these women with polycystic ovaries shown on ultrasound will have classical symptoms of polycystic ovarian syndrome such as infertility, amenorrhea and obesity.<sup>6</sup> The

diagnosis of polycystic ovarian syndrome (PCOS) requires the exclusion of all other disorders that can result in menstrual irregularity and hyperandrogenism.<sup>7</sup> The morphology of polycystic ovary has been defined as an ovary with 12 or more follicles measuring 2-9mm and/or increased ovarian volume ( $>10 \text{ cm}^3$ ).<sup>8</sup>

Early Doppler ultrasound studies have demonstrated increased stromal vascularity in polycystic ovaries.<sup>9</sup> The optimal timing of ultrasonography to diagnose PCO's is probably during follicular phase (day 3-5 of menstrual cycle).<sup>10</sup> Blood flow analysis of the uterine and ovarian arteries also revealed modifications of hemodynamic profiles in patients with amenorrhea. Peak systolic velocity and end-diastolic velocities underwent greater modification in amenorrhoeic patients, being significantly lower when compared with that of controls in both the uterine and ovarian arteries.<sup>11</sup>

Main rationale of this study is recent interest in this topic, a non invasive approach, less time consuming, easy availability of Doppler ultrasound and its sensitivity in diagnosis of polycystic ovaries. Literature shows variability in blood flow patterns, PI and RI values. Secondly I wanted to determine the correctly diagnosed cases using uterine artery PI and RI on doppler because if found acceptable then reliability on hormonal level is no more needed for diagnosis of polycystic ovaries. Moreover transabdominal doppler scan has easy availability plus with uterine artery doppler indices one should give strong recommendation about polycystic ovaries. In plain pelvic ultrasound we at times can not give the confirm diagnosis due to patient and diseases variability and also sometimes difference in plain pelvic ultrasound findings and hormonal profiles noted.

## Patients and Methods

It was a cross-sectional survey. The study was conducted in the Radiology Department of Combined Military Hospital, Lahore from September 2012 to march 2013. Approval from the hospital ethical review committee was acquired prior to the start of this study.

Sample size of 120 cases was calculated with 95% confidence level, 7% margin of error and taking expected percentage of correctly diagnosed cases of PI of uterine artery on doppler in diagnosis of PCOS i.e. 83%. Non probability purposive sampling technique was used. Each patient is examined in the cycle, during cycle day 8-16, in order to rule out any pathology preventing the treatment. Where a corpus luteum was visible ultrasonographically the patient was excluded from the study. The ovaries were categorized as either normal (N) or polycystic (PCO) according to the following criteria of Rotterdam ESHRE-ASRM-sponsored PCOS Consensus Workshop Group (2004). When 2 out of the following 3 criteria were present: 1. Oligomenorrhea (<6 menstrual periods in preceding year) and/or anovulation: clinical/biochemical signs of hyperandrogenism; 2. Increased ovarian volume of more than 10 cm<sup>3</sup>; 3. Twelve or more follicles measuring 2-9mm.

Woman taking oral contraceptive pills, with biochemical evidence of hyperprolactinemia, thyroid disease or congenital adrenal hyperplasia, based on screening laboratory investigation and PCO in the absence of an ovulation disorder or hyperandrogenism ('asymptomatic PCO'), were excluded. Pulsatility Index was the measure of the variability of blood velocity in a vessel and was measured as:

Pulsatility index = (S-D)/mean

Right + Left uterine artery Pulsatility index

Where S is peak systolic Doppler frequency shift, D is minimum Doppler frequency shift and mean is the time averaged maximum Doppler frequency

Resistive index was taken as an indicator of resistance of an organ to perfusion. In ultrasonography, it can be calculated from the peak systolic velocity and the end diastolic velocity of blood flow. Resistance Index = (Peak systolic - end diastolic) / (Peak systolic)

Each measurement was repeated at least 3 times and averaged. The uterine artery was visualized laterally to cervix at the level of internal os in a longitudinal plane. The pulsed Doppler sample volume was placed across the vessel with the angle between the ultrasound beam and the vessel close to 0 degree. Flow velocity waveforms were obtained and PI and RI were calculated as  $PI = (S-D)/\text{mean}$  and  $RI = (S-D)/S$ , where as S was the peak systolic frequency Doppler frequency shift, D was minimum Doppler frequency shift and mean is the time averaged maximum Doppler frequency shift over 1 cardiac cycle. Four waveforms were recorded and averaged for calculations. PI value of  $\geq 1.02$  was taken as positive

for PCOS on doppler to determine the frequency of correctly diagnosed cases.

## Results

There were 49 (40.8%) patients in the age group 20 - 25 years, 41 (34.2%) patients in the age group 26 - 30 years, 21 (17.5%) patients in the age group 31 - 35 years and 9 (7.5%) patients of age 36 - 40 years. None of the patients was of age more than 40 years. The mean age of the patients was  $24.34 \pm 4.01$  years. The age range was from 20 years to 37 years. (Table 1). Of the 120 patients included in the study, there were 101 (84.2%) patients in whom the power doppler scan correctly diagnosed the cases and it could not be diagnosed correctly in 19 (15.8%) patients in the study. (Table 2; Figures 1-4). The mean pulsatility index and resistive index of 120 patients (including both right and left ovarian arteries) was  $3.89 \pm 0.76$  and  $0.93 \pm 0.10$ . (Table 3)

Table 1. Patients' distribution (n=120)

Age in years	No	Percentage
20 - 25	49	40.8
26 - 30	41	34.2
31 - 35	21	17.5
36 - 40	9	7.5
> 40	0	0
Mean + SD	$24.34 \pm 4.01$	
Range	20 - 37	

Table 2: Distribution of patients by frequency of correctly diagnosed cases

Results	No(%)
Correctly diagnosed	101 (84.2%)
Not correctly diagnosed	19 (15.8%)

Table 3: Distribution of patients by Mean of Pulsatility index and resistive index

Variables	Mean + SD
Pulsatility Index	$3.89 \pm 0.76$
Resistive Index	$0.93 \pm 0.10$

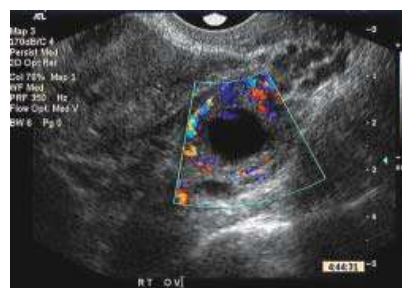

Figure 1: Color Doppler image of the ovarian blood flow in the luteal phase of the cycle

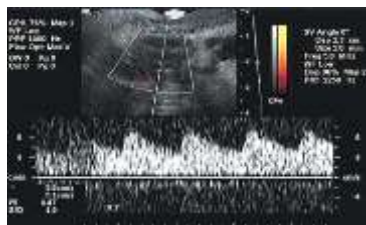


Figure 2: Doppler waveform analysis of the blood flow of uterine artery stroma. Note the low resistance to blood flow

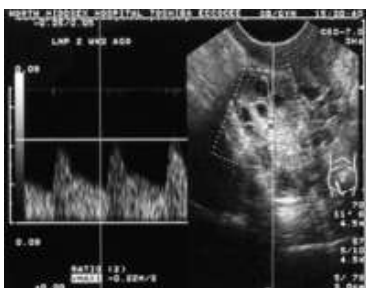

Figure 3: A typical flow velocity diagram at the stroma shows higher uterine artery velocity in a 35-year-old polycystic ovary syndrome patient

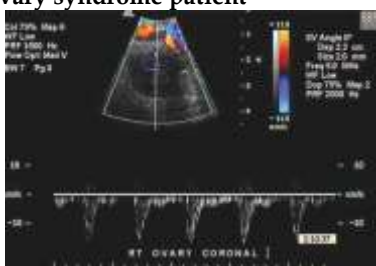


Figure 4: The uterine artery color and pulsed Doppler. Note the low resistance to blood flow using transabdominal color Doppler

## Discussion

In present study, we used indices of colour Doppler ultrasound were used for diagnosis of PCO. It is noninvasive assessment of blood flow. Different studies however shown conflict in values of mean resistance index (RI) and mean Pulsatility index (PI) of uterine artery in diagnosis of PCOS. A study "PCOS: Assessment with colour doppler angiography and three dimensional ultrasonography" concluded that uterine artery PI and RI are both raised in PCOS.<sup>12</sup> Another study "Polycystic ovary syndrome: relationship between insulin sensitivity, sex hormone levels and ovarian stromal blood flows" concluded that mean uterine artery PI and RI were both decreased in PCO.<sup>13</sup> Another study "The evaluation of blood flow in uterine arteries in girls with polycystic ovary syndrome by Transvaginal colour doppler ultrasonography" shows only elevated uterine artery PI was observed in PCOS patients.<sup>14</sup>

A number of studies of Color Doppler measurement of uterine and ovarian vessel blood flow have demonstrated a low resistance index in the stroma of polycystic ovaries and correlations with endocrine changes. One of these groups reported a good correlation between serum androstenedione LH: FSH ratio and also correlated well with the stromal artery pulsatility index (PI).<sup>15</sup>

The frequency of correctly diagnosed cases (i.e. 84.2%) in our study is consistent with another study conducted by Battaglia C, et al<sup>16</sup> in which power Doppler scan could detect correctly in 83% cases. Like our study, they also adopted a cut off value of  $\geq 1.20$  for diagnosis of the PCOS. The results of both the studies show that power Doppler scan is suitable for detection of the cases with polycystic ovarian disease with a high frequency of correctly diagnosed cases.

The mean Pulsatility index was high ( $3.89 \pm 0.76$ ) in our study and resistive index was on lower side i.e.  $0.93 \pm 0.10$ . Dolz M, et al<sup>17</sup> also conducted a similar study to determine whether there lies any difference in pulsatility index and resistive index. Like our study, they documented a high PI in patients with PCOS i.e.  $3.56 \pm 0.93 < 2.55 \pm 0.63$   $0.001$ . They determined that RI in patients with PCOS was  $0.94 \pm 0.06$  and in controls it was  $0.86 \pm 0.06$  and the difference was statistically significant ( $P < 0.05$ ).

Goswamy and Steptoe<sup>18</sup> were the first to report significantly elevated RI and PI values in the uterine arteries of infertile women who had PCOS. The RI was found to be inversely related to the intraovarian flow RI in these patients. These findings suggest that as the uterine artery impedance increases, intraovarian flow also increases.

Although intraovarian vessels normally are not visible before days 8 to 10 of the cycle, these vessels are seen between days 3 and 5 in patients with PCO. Furthermore, an inverse correlation is found between LH/FSH ratio and Doppler sonographic indices in these patients. Our observations of altered ovarian blood flow in patients with PCOS were consistent with the reports of these investigators. We were able to confirm that the RI and PI values in the ovarian stroma of polycystic ovaries are similar to those found in corpora lutea. Doppler sonographic studies indicate that polycystic ovaries have a greater number of vessels than is found in normal ovaries during the initial phase of folliculogenesis.

## Conclusion

The frequency of correctly diagnosed cases of PCOS with pelvic colour doppler was high. So, its use should be encouraged for detection of PCO in suspected cases.

The cut off value of  $\geq 1.02$  PI may predict the cases in majority of the cases. A high pulsatility index and low resistivity index of uterine artery was observed in our study.

## References

1. Hart R. Definition, prevalence & symptoms of polycystic ovaries & polycystic ovarian syndrome. In Allahbadia G, Agrawal R, editors. Polycystic ovarian syndrome. 1st ed. UK: Anshan Limited; 2007. P.15-26.
2. Xita N and Tsatsoulis A. Fetal programming of polycystic ovary syndrome by Androgen excess. *Journal of Clinical Endocrinology and Metabolism*. 2006;5:1660-66.
3. Azziz R, Carmina E, Dewailly D, Diamanti-Kandarakis E. The Androgen Excess and PCOS Society criteria for the polycystic ovary syndrome: the complete task force report. *Fertil Steril* 2009;91:456-88.
4. Barber TM and Franks S. Genetic basis of polycystic ovary syndrome. *Expert Rev Endocrinol Metab*. 2010;5:549-52.
5. Stein I and Leventhal M. Amenorrhea associated with bilateral polycystic ovaries. *Am J Obstet Gynecol*. 1935;29:181-84.
6. Lakhani K, Seifalian AM, Atiomo WU, Hardiman P. Polycystic ovaries. *Br J Radiology*, 2002;75:9-16
7. American College of Obstetricians and Gynecologists. Polycystic ovary syndrome. Washington, DC: American College of Obstetricians and Gynecologists; 2009. ACOG practice bulletin; no. 108.
8. Balen A H. What is new in polycystic ovarian syndrome. In: Bonnar J, Dunlop W, editors. Recent advances in obstetrics and gynecology. 2<sup>nd</sup> ed. UK: Royal society of Medicine Press; 2005. P.147-58.
9. Pan HA, Wu Meng, Cheng YU, Hsien CH, Chang FM. Quantification of doppler signal in polycystic ovary syndrome using three-dimensional power Doppler ultrasonography: a possible new marker for diagnosis *Oxford Journals Human Reproduction* 2001;17:201-06.
10. Maslovitz S, Jaffa A. Ultrasound appearance of polycystic ovaries & ovarian hyperstimulation syndrome. In Allahbadia G, Agrawal R, editors. Polycystic ovarian syndrome. 1st ed. UK: Anshan Ltd; 2007. P.57-67.
11. Pellizzari P, Esposito C, Siliotti F, Marchiori S, Gangemi M. Colour doppler analysis of ovarian and uterine arteries in women with hypoestrogenic amenorrhoea *Oxford Journals Human Reproduction* 2002;17:3208-12.
12. Mala YM, Ghosh SB, Tripathi R. Three-dimensional power Doppler imaging in the diagnosis of polycystic ovary syndrome *Int J Gynaecol Obstet*, 2009;105:36-38.
13. Loverro G, Vicino M, Lorusso F, Vimercati A. Polycystic ovary syndrome: relationship between insulin sensitivity, sex hormone levels and ovarian stromal blood flow. *Gynecol Endocrinol* 2001;15:142-49.
14. Maciolek-Blewniewska G, Kozarzewski M, Szpakowski M. The evaluation of blood flow in uterine arteries in girls with polycystic ovary syndrome by Transvaginal colour doppler ultrasonography, 1999;70:412-17.
15. Balen AH, Laven JSE, Tan SL, Dewailly D. Ultrasound assessment of the polycystic ovary: international consensus definitions. *Human Reproduction Update*. 2003;9:505-14.
16. Battaglia C, Battaglia B, Morotti E, Paradisi R. Two- and three-dimensional sonographic and color Doppler techniques for diagnosis of polycystic ovary syndrome. The stromal/ovarian volume ratio as a new diagnostic criterion. *J Ultrasound Med*, 2012; 31:1015-24
17. Dolz M, Osborne NG, Blanes J, Raga F. Polycystic Ovarian Syndrome: Assessment with Color Doppler Angiography and Three-Dimensional Ultrasonography. *J Ultrasound Med* 1999;18:303-13.
18. Goswamy RK and Steptoe PC: Doppler ultrasound studies of the uterine artery in spontaneous ovarian cycles. *Hum Reprod* 3:721, 198