

# Changes in Arrangement of Chondrons in Radial Zone of Ageing Male Human Articular Cartilage

Shaista Ali <sup>1</sup>, Samia Sarwar <sup>2</sup>, Ifra Saeed <sup>3</sup>

1. Department of Anatomy, HBS Medical and Dental College Islamabad; 2. Department of Physiology, Rawalpindi Medical College, Rawalpindi; 3. Department of Anatomy, Rawalpindi Medical College, Rawalpindi

## Abstract

**Background:** To study the variation in arrangement of chondrons in radial zone of male human articular cartilage.

**Methods:** Forty samples of articular cartilage from male dead bodies ageing between 21 – 60 years were collected and divided into four groups. After tissue processing and cutting, H&E and special staining with Masson's Trichrome was done and arrangement of chondrons was noted.

**Results:** With advancing age the arrangements of chondrons in radial zone of group A, B and C was in short columns while in group D, the arrangement was disturbed. The chondrons were observed in pairs and clusters.

**Conclusion:** In ageing articular cartilage the arrangements of chondrons in radial zone of articular cartilage is altered leading to osteoarthritis that makes it focus of intense study for preventive measures and treatment.

**Key words:** Articular cartilage, Chondrons, Radial zone, Osteoarthritis

## Introduction

Articular cartilage is a specialized supporting connective tissue that covers the ends of the bones in synovial joints.<sup>1</sup> Its unique structural and metabolic properties provide extraordinary resilience to the joint and ability to withstand enormous pressure.<sup>2-4</sup> Histologically, there are four zones of articular cartilage. Three of them namely tangential, transitional and radial zones are non-calcified while the calcified cartilage zone is the deepest zone. Type II collagen is most abundant of the collagen fibres and constitutes about 95% of the total collagen content of AC.<sup>5</sup> The chondrons in each of these zones have specific arrangement and secrete the particular components of the ground substance in specific concentration and orientation.<sup>6</sup> The unique biomechanical properties of the articular cartilage are due to the complex architectural arrangement of the collagen network and the non-homogenous spatial

distribution of collagen, proteoglycans and water in the tissue.<sup>6-8</sup>

Radial zone, also called the deep layer forms the third and the largest zone of articular cartilage. Chondrons are spherical in shape, arranged in short, irregular vertical columns (5-7 cells/column) as compared to the horizontal arrangement of chondrons in tangential zone and random pairs and groups of chondrons in transitional and calcified cartilage zones. Collagen fibres are also arranged perpendicular to the surface, in vertical columns in radial zone.<sup>3,5</sup>

Degeneration of articular cartilage leads to osteoarthritis, a most common age related degenerative joint disease and a primary cause of pain and disability. It is characterized by progressive cartilage degeneration, clustering of chondrocytes instead of particular zonal arrangement and loss of chondrocytes and proteoglycans.<sup>9</sup> There are approximately 46 million patient visiting hospitals for osteoarthritis each year in the US.<sup>9</sup> In year 2004, about 430,000 of the hospital discharges were knee osteoarthritis costing \$14 billion of hospital charges in the United States.<sup>10</sup> Sixty percent of men living up to seventh decade suffer from knee osteoarthritis.<sup>11</sup> Although the epidemiology of osteoarthritis in the developing world is much less known and the overall data is sparse, according to Chopra and Abdul Nasser in 2008, the prevalence % of osteoarthritis knee was 5.8 in India, 9.6 in China, 11.3 in Indonesia and 7.5 in Bangladesh.<sup>12</sup>

## Material and Methods

Forty samples of articular cartilage of knee joint were collected from unknown male dead bodies from Forensic department of King Edward Medical University, Lahore within six hours of death. All the bodies were between 21-60 years of age. The autopsy was performed within 12 hours, till that time the temperature of bodies was maintained at 4°C. Depending upon the age of the cadaver, the collected samples of articular cartilage were divided in four groups, i.e., Group A: 21 – 30 years, Group B: 31 –

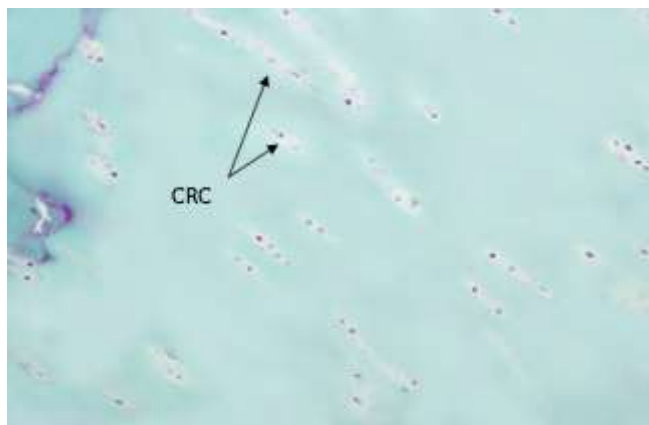
40 years. Group C: 41 – 50 years. Group D: 51 – 60 years. For this study articular cartilage of femoral condyle of right sided knee joint was selected. Transverse incision was given on the skin extending from medial to lateral epicondyle of femur. Skin was retracted upwards and downwards to expose the quadriceps tendon. This tendon was cut by giving inverted “U” shaped incision starting above the patella and extending downwards to the tibial condyle on either side of ligamentum patellae. The cut tendon was reflected downwards along with patella to expose the articular cartilage of femoral condyle. Knee joint was flexed and 1 cm x 1 cm full thickness piece of articular cartilage was removed with the chisel from the tibial surface of femoral condyle, 1 cm medial to the medial margin of intercondylar fossa. The specimens were immediately placed in 10% neutral buffered formalin for 48 hour, processed for paraffin embedding. Five micrometer (5µm) thick sections were made on rotary microtome and mounted on clear albumin coated slides. Masson’s Trichrome stain was done and arrangement of chondrons in radial zone was noted in all groups. Chi square test was used for comparison in all study groups. Arrangement of chondron in radial zone was in small column 5-8 chondrons/column in all samples of group A, B and group C and in 8 samples of group D.

### Results

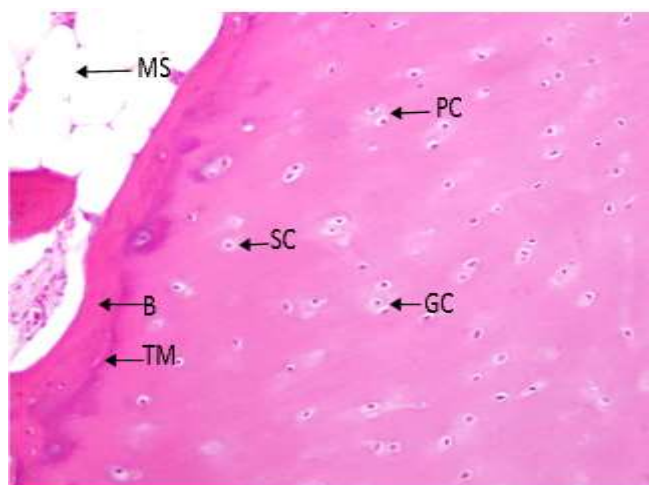
In 2 samples of group D, zonal arrangement was disturbed and the chondrons were present in pairs or arranged in groups or clusters instead of columns. Some single chondrons were also seen. Arrangement of chondron in radial zone was varying with advancing age and demarcation between radial zone and transitional zone was not possible because of the similar arrangement of chondrons in transitional zone disturbing the normal structure (*p*-value = 0.097) (Table 1; Figure 1&2).

**Table 1:Arrangement of chondrons in radial zone**

Study groups	Number of samples	Column arrangement of chnodrons	Disturbed column arrangement of chondrons
A	10	10	00
B	10	10	00
C	10	10	00
D	10	08	02
Over all <i>p</i> - value = 0.097			



**Fig 1.Histomicrograph of articular cartilage from 42 year old male (group c) showing round chondron arranged in columns in the radial zone (Masson’s Trichrome 20X);Arrows showing column arrangement of chondron**



**Fig 2.Histomicrograph of articular cartilage from 58 year old male (group D) showing disturbed arrangement of chondron in the radial zone - no column are seen, only single, paired and grouped chondron are visible (H & E 20X);Arrows showing:Paired Chondrons;Single Chondron;Group of Chondron;Tide Mark;Bone Marrow Space**

### Discussion

This study describes the histomorphometric analysis of ageing male articular cartilage and the degenerative changes related to the advancing age. In this study it was observed that in the radial zone, the arrangement of chondron was in short columns in all samples of group A, B, C and in 8 samples of group D. These findings were similar to the study of Bhosale and Richardson (2008) and Gupta and Goyal (2006) who observed the columns of chondrons in the radial zone of articular cartilage. <sup>13, 14</sup>

In 2 samples of group D, the chondrons in radial zone were not arranged in columns rather they appeared to be present in clusters or groups, some paired arrangement was also noted and few chondrons were seen isolated as well. Zonal arrangement was disturbed and no demarcation was present between transitional and radial zone because this is the normal arrangement of chondrons for the transitional zone. These findings were similar to Lotz M K et al who observed that altered cell patterns in the radial zone are thought to be derived from cell proliferation, probably also cell migration and the formation and specific organization of the ECM during ageing. A significant loss of mechanical properties is correlated with the loss of pericellular type IV collagen. This change not only shortens the diffusion distance for nutrients and cell mediators from the synovial fluid but also of cluster-derived mediators to the synovial space.<sup>6</sup> Gupta and Goyal (2006) described this as the result of ageing and degenerative process.<sup>14</sup> They observed such change at 70 years of age while in this study this change in the zonal arrangement was seen in the samples of up to 60 years. Such early degenerative changes might be related to specific dietary habits, nutritional deficiencies and the life style of the people in a population. Chi et al (2004) described that in early osteoarthritis, chondrocytes undergo transient phase of proliferation as a compensatory phenomenon. This proliferation appears as clustering of chondrocytes in pairs or groups in ageing cartilage.<sup>15</sup> Similar picture is seen in osteoarthritis. This phenomenon may be understood as recapitulation of the events of development in which there was complete division of a cell but incomplete division of chondrons microenvironment. Chondrocytes thus appear to be present in groups or clusters.<sup>3</sup> It is suggested that a lot more research work is required to explore the causes of early onset of degenerative process, especially in Pakistani population so that a guideline can be formulated for prevention of joint disease and improvement in the quality of life of our population.

### **Conclusion**

In ageing articular cartilage the arrangement of chondrons in radial zone changes from short columns

to isolated, paired or group of chondrons leading to osteoarthritis.

### **References**

1. Musumeci G, Castrogiovanni P. New perspective for articular cartilage repair treatment through tissue engineering: A contemporary review. *WJO World Journal of Orthopedics* 2014; 5(2): 80-88
2. Ofek G, Revell CM, Hu JC, Allison DD, Grande-Allen KJ. Matrix development in self-assembly of articular cartilage. *Plos one* 2008; 3(7): 2795-805.
3. Chi SS, Rattner JB, Matyas JR. Communication between paired chondrons in the superficial zone of articular cartilage. *J Anat* 2004; 205(5): 363-70.
4. Ackermann B and Steinmeyer J. Collagen biosynthesis of mechanically loaded articular cartilage explants. *Osteoarthritis and Cartilage* 2005; 13: 906- 914
5. Wheelers. *Articular Cartilage*. [On Line] Available from URL:<http://www.Wheelsonline.com/ortho/articularcartilage> [Cited on June 14, 2010].
6. Lotz MK, Otsuki S, Grogan SP, Sah R, Terkeltaub R, Lima DD. Cartilage cell clusters Arthritis Rheum 2010 ; 62(8): 2206-18.
7. Berenbaum F. Osteoarthritis is an inflammatory disease (osteoarthritis is not osteoarthritis). *Osteoarthritis and Cartilage* 2013; 21(1): 16-21.
8. Rieppo J, Hyttinen MM, Halsmaki E. Changes in spatial collagen content and collagen network architecture in porcine articular cartilage during growth and maturation. *Osteoarthritis and Cartilage* 2009; 17: 448-55
9. Karsdal MA, Michialis M, Ladel C. Disease modifying treatments for osteoarthritis (DMOADs) of the knee and hip: lessons learned from failures and opportunities for the future. *Osteoarthritis and Cartilage* 2016; 24(12): 2013-21.
10. Murphy L, Schwartz TA, Helmick CG. Life time risk of symptomatic knee osteoarthritis. *Arthritis and Rheumatism* 2008; 59(9): 1207-13.
11. Arden N and Nevitt M. C. Osteoarthritis: Epidemiology. *Best Practice and Research Clinical Rheumatology* 2006; 20(1): 3-25.
12. Chopra A and Abdel-nasser A. Epidemiology of rheumatic musculoskeletal disorder in the developing world. *Best Practice and Research Clinical Rheumatology* 2008; 22(4): 583-604.
13. Gupta M and Goyal N. Age changes in the microscopic structure of human femoral articular cartilage. *J Anat* 2006; 55(2): 15-18.
14. Bhosale AM and Richardson AR. Articular cartilage: structure, injuries and review of management. *British Medical Bulletin* 2008; 87: 77-95.
15. Van der Kreef PM, Van der Berg WB. Chondrocyte hypertrophy and osteoarthritis: role in initiation and progression of cartilage degeneration?. *Osteoarthritis and Cartilage* 2012; 20(3): 223-32.