

Role of CXR and HRCT in diagnosing COVID-19, a descriptive cross-sectional study, at a tertiary care hospital in Pakistan

Hina Hanif Mughal¹, Madiha Maryam Azam², Faryal Azher³, Nasir Khan⁴, Sadia Chaudhry⁵, Hina Sattar⁶

¹ Assistant Professor & HOD, Department of Radiology, Benazir Bhutto Hospital, Rawalpindi.

² Post-graduate Trainee, Department of Radiology, Holy Family Hospital, Rawalpindi.

³ Associate Professor, Department of Surgery, Allama Iqbal Medical College, Lahore.

⁴ Professor, Department of Radiology, Rawalpindi Medical University, Rawalpindi.

⁵ Associate Professor & HOD, Department of ENT, Rawalpindi Medical University, Rawalpindi.

⁶ Assistant Professor, District Headquarter Hospital, Rawalpindi

Author's Contribution

^{1,2,4,5} Conception of study

^{2,3} Experimentation/Study conduction

^{3,5,6} Analysis/Interpretation/Discussion

⁶ Manuscript Writing

⁵ Critical Review

⁵ Facilitation and Material analysis

Corresponding Author

Dr. Hina Hanif Mughal,

Assistant Professor & HOD,

Department of Radiology,

Benazir Bhutto Hospital,

Rawalpindi.

Email: dr.hinahanif@gmail.com

Article Processing

Received: 24/04/2021

Accepted: 06/12/2021

Cite this Article: Mughal, H.H., Azam, M.M., Azher, F., Khan, N., Chaudhry, S., Sattar, S. Role of CXR and HRCT in diagnosing COVID-19, a descriptive cross-sectional study, at a tertiary care hospital in Pakistan. *Journal of Rawalpindi Medical College*. 31 Dec. 2021; 25(4): 457-461.

DOI: <https://doi.org/10.37939/jrmmc.v25i4.1637>

Conflict of Interest: Nil

Funding Source: Nil

Access Online:



Abstract

Objectives: The objective of this study is to do the analysis of chest X-ray and High-resolution CT scan findings in patients who are clinical suspects of COVID-19 infection. The other objective is to classify the radiological findings in mild, moderate or severe diseases according to BSTI criteria for chest X-ray and CTSS for high-resolution CT scan.

Materials and Methods: This is a cross-sectional descriptive study. A group of 50 patients who were clinically suspected cases of COVID-19 infection, presented to Corona flu filter clinic of Holy Family Hospital (HFH) or admitted to corona isolation wards were included. The time duration of the study was from 15 May 2020 to 15 June 2020. All radiological findings were analyzed based upon the Fleischner society glossary of terms for thoracic imaging.

Results: Out of 50 patients, 33(66%) were males, and 17(34%) were females. The mean age was 51 with ages ranging from 30-72 years. On CXR, 5(10%) patients showed classic findings which were highly probable for COVID-19. 19(38%) patients showed intermediate results for COVID-19, 7(14%) patients had a low probability of COVID-19 infection on CXRS. Out of 50, 19(38%) patients showed normal CXR with no evidence of COVID-19 infection. HRCT of the same patients were acquired on the same day; it showed 21(42%) patients with mild disease, 23(46%) patients with moderate disease and 6(12%) patients with severe disease according to CTSS. HRCT of 3(6%) patients showed no evidence of illness in bilateral lung fields.

Conclusion: The role of radiology is crucial in the diagnosis of this viral illness. CXR, with its ability to detect changes of COVID-19 in lungs, should be used as a first-line imaging modality in clinically suspected patients.

Key Words: Chest X-ray, HRCT, COVID-19, CT-SS, BSTI.

Introduction

In Nov and Dec of 2019, the novel coronavirus (COVID-19) that causes respiratory tract infection emerged as a local outbreak in the city of Wuhan, China with 80,000 confirmed cases and 31,000 deaths in China.¹ On 11 March, WHO declared COVID-19 as a global pandemic.² It resulted in the sporadic transmission of disease in the majority of countries of the world, putting a burden over health care delivery, hospital beds, ventilators and health care workers as well as diagnostic testing.³ Respiratory dysfunction is a major cause of morbidity and mortality in severe cases.⁴ PCR (identification of viral pathogen via nucleic acid detection) was declared as the gold standard for diagnosis of COVID-19.⁵ However, radiological imaging is yet the main clinical diagnostic tool for COVID-19 infection. This crucial role of radiology in rapid identification and early diagnosis of suspected patients can be of great benefit not only to patients but also to public health surveillance and response system.⁶ CXR and HRCT are the most sensitive radiological diagnostic tools. Chest X-ray is relatively insensitive to the early stages of COVID-19. However, it still serves as a screening tool as a front line imaging modality in medical settings with limited resources. The limitations were, in cases where patients cannot be transported to the CT scanner. The others were in situations where inefficiencies related to CT decontamination are common, in settings where CT facility is not altogether present and in patients to whom the burden of radiation dose exceeds the benefit of diagnosis. Furthermore, CXR if abnormal or suggestive of COVID-19 infection, may obviate the need for HRCT.⁷

HRCT is very sensitive in the detection of early disease, to assess the nature, the extent of abnormalities in lungs, assess the nature and extent of lesions and to discover subtle changes that are often not visible on CXR.⁸

The typical CXR and HRCT imaging characteristics of COVID-19 include multiple bilateral peripheral areas of ground-glass haze and patches on consolidation mostly in bi basal lung fields.⁹

Objectives:

The main objectives of this study were:

- To analyze CXR findings in the diagnosis of COVID-19 infection.
- To classify the findings on CXR in mild/moderate and severe disease according to BSTI criteria.

- To analyze HRCT findings in the same patients in order to assess the disease severity using CTSS.

Materials and Methods

Study design

It was a cross-sectional descriptive study.

Inclusion Criteria

Patients who were clinically suspected cases of COVID-19 infection and presented to Corona flu filter clinic of HFH or admitted to DID corona isolation wards.

Patients clinically labelled as suspected cases, having positive contact with a confirmed positive patient of COVID-19 infection based upon positive PCR, or recent travel history from the area having an outbreak and was having clinical signs/symptoms of fever, cough, shortness of breath, lethargy and loss of sense of smell or taste.

Exclusion criteria

All patients who were having ongoing lung disease i. e tuberculosis, lung malignancy, interstitial lung disease and those who cannot be transported to CT suite (on ventilatory support) were excluded from the study.

Data Collection and analysis

Informed consent was taken from all patients enrolled in the study. CXR and subsequent HRCT were done on the same day in all these 50 patients. PCR correlation was also made at the time of history. Baseline demographic data was collected from patients. All radiological findings were analyzed based upon the Fleischer society glossary of terms for thoracic imaging.¹⁰

CXR was done using a digital radiography machine (Toshiba KXO 80X). The most common CXR findings were air space opacities, ground-glass haze and patches of consolidation in bilateral basal lung segments. Two consultant radiologists then assessed CXRs findings based upon BSTI criteria and labelled those CXR findings as low probability, moderate and high probability for COVID-19 infection.

Subsequent HRCT was done on the same day using a multi-detector (16) Toshiba Aquilion CT scanner with a slice thickness of 1.0mm and reconstruction interval of 1-3mm. CT was performed with patients in the supine position and breath-hold in full inspiration without any oral and intravenous contrast material. Images obtained were assessed using mediastinal and lung windows.

CT findings were analyzed using CTSS and labelled as mild, moderate and severe disease. The most common

findings on HRCT were multifocal areas of ground-glass haze, peripheral patches of consolidation with air bronchograms and crazy paving patterns. A comparison was made between findings on CXR and HRCT, and results were analyzed using SPSS 25. The study was approved by the ethical board of the hospital.

Results

Out of 50 patients, 33(66%) were males, and 17(34%) were females. The mean age was 51 with ages ranging from 30-72 years. Presenting complaints were fever in 42(84%) patients, shortness of breath in 41(82%) cough in 37(74%), lethargy in 33(66%), and loss of sense of smell and taste in 21(42%) patients. Out of these 50 patients, 32(72%) were having positive PCR for COVID-19 infection. When analysis of chest X-ray findings was done, 5(10%) patients showed classic findings which were highly probable for COVID-19 and 19(38%) patients showed intermediate findings for COVID-19. Rest of 7(14%) patients had a low probability of COVID-19 infection on CXRS. Out of 50, 19(38%) patients showed normal CXR with no evidence of COVID-19 infection.

When HRCT of the same patients was done on the same day, it showed 21(42%) patients with mild disease, 23(46%) patients with moderate disease and 6(12%) patients with severe disease according to CTSS. HRCT of 3(6%) patients were normal, with no evidence of disease in bilateral lung fields.

CXR was able to detect disease in 62% of patients. These results are comparable to the reported sensitivity of CXR as 69% in the literature.¹¹ Rest of 38% of patients were reported as normal on x-ray. CT, on the other hand, reported 94% of patients as having disease positive. This percentage is comparable to the already reported 97% in literature¹² for diagnosis of COVID-19 infection.

All these patients were clinically suspected cases of COVID-19 infection, but only 64% of patients showed up positive PCR test which is again comparable to the reported sensitivity of PCR as 61-71% (see Table 2).

When a comparison of CXR and HRCT findings was made, it was concluded that CXR was unable to detect mild disease of COVID-19 pneumonia as it detected 14% of patients with low probability as compared to 42% detected by CT scan as a mild form of the disease. The percentage of CXR in assessing moderate to severe probability was comparable to HRCT assessment of moderate to severe diseases (see Table 3).

Other findings included unilateral pleural effusion in 4(8%) patients, mediastinal lymphadenopathy in 2(4%) patients and bronchiectasis cavity in 2(4%) patients.

BSTI Criteria was formulated by the British Society of Thoracic Imaging for grading of CXR findings of COVID-19 in normal, classic/high probability, intermediate probability and non-COVID. This criterion was published on 16 March 2020.

CTSS was defined by summing up individual scores from 20 lung regions. Scores of 0, 1, 2 were respectively assigned for each region if parenchymal opacification involved 0%, less than 50%, or more than 50% of each region (theoretical range of CT-SS from 0-40).

Table 1: Frequencies & Percentages of various symptoms of COVID-19 infection

		Frequency	Percentage
Fever	Present	42	84%
	Absent	8	16%
Cough	Present	37	74%
	Absent	13	26%
Shortness of breath	Present	41	82%
	Absent	9	18%
Lethargy (a)	Present	39	78%
	Absent	11	22%
Loss of taste and smell (b)	Present	29	58%
	Absent	21	42%

Table 2: Frequency & Percentage against PCR test for Covid-19 infection

PCR	Frequency	Percentage
Positive	32	64
Negative	18	36

Table 3: comparison of CXR and HRCT findings in assessing covid-19 infection

	CXR		CT-Scan	
	Freque ncy	Perce ntag e	Freque ncy	Perce ntag e
Normal	19	38%	3	6%
Low probability	7	14%	21	42%
Intermediate probability	19	38%	23	46%
High probability	5	10%	6	12%

Table 4: Comparison of CXR findings with PCR results in covid-19 infection

	CXR		PCR	
	Frequency	Percent age	Positive	Negative
Normal	19	38%	15	4
Low probability	7	14%	3	4
Intermediate probability	19	38%	11	8
High probability	5	10%	3	2

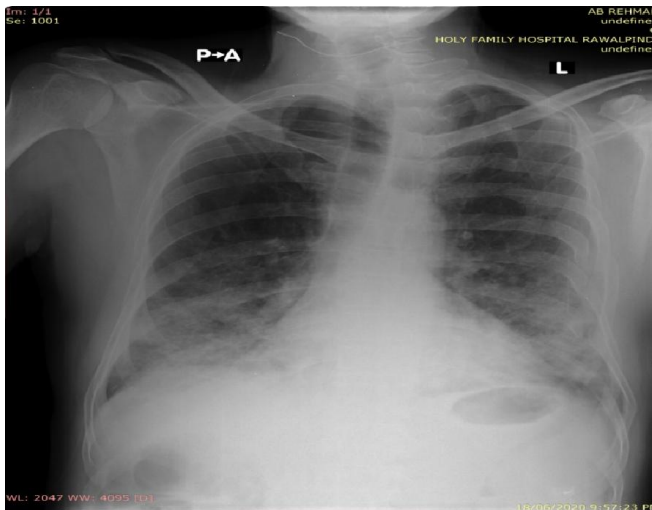


Figure 1: CXR PA view of 49 years old male patient showing multiple peripheral patches of consolidation in bilateral lower lungs. Findings were highly probable for covid-19 infection.

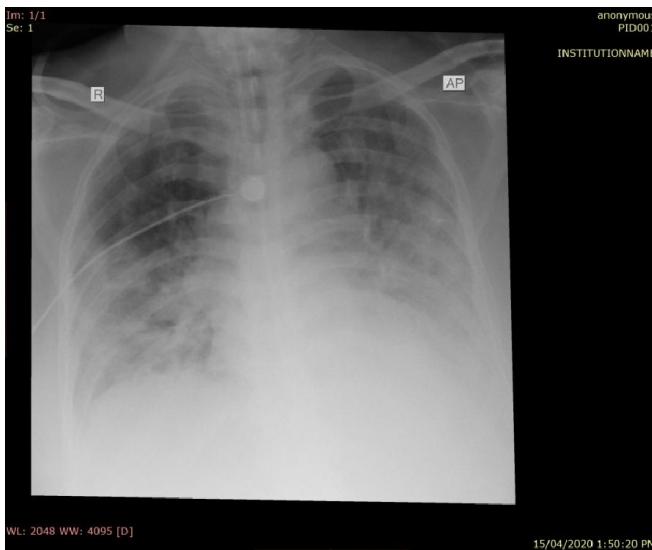


Figure 2: CXR AP view of 56 years old male patient showing patchy areas of air space shadowing and

patches of consolidation in bilateral mild and lower lung zones. Findings are having a moderate probability for covid-19 infection.

Discussion

Chest X-ray is the basic investigation in the diagnosis of COVID-19 as the patient is shifted to the Corona unit on its basis. This should be used as the first-line of assessment of patients with corona positive or suspected cases.^{13,16} HRCT chest is a better option than chest X-ray in identifying the patient with COVID-19 though more expensive, not available in deprived areas, not readily available and can be difficult to perform. We performed both Chest X-ray and CT scans in all our 50 patients. Both are beneficial for confirming patients with corona.

The more appropriate is chest X-ray then CT scan in confirming the diagnosis of Coronavirus. Radiography has a pivotal role in diagnosing COVID-19 patients. Milder forms of the disease can be missed by only doing X-rays and so we did X-ray and CT scan both to detect disease at its initial stage.¹⁷ The health professionals from China did only CT scan chest for COVID-19.¹⁴

The Chest X-ray and CT both are beneficial even if the PCR was negative. The management of patients can be monitored by using serial chest X-rays. The typical chest X-ray findings in our study were the ground glass appearance, peripheral haze, consolidation in the lungs. Pleural effusion was only found in a few percent of patients. Geoffrey et al in their study explained the limited use of radiography in corona patients with mild disease. There is an established role of radiography in the management of COVID19 patients by doing serial chest X-rays.^{14,16}

Conclusion

The role of radiology is crucial in the diagnosis of COVID-19 infection. CXR, with its ability to detect changes of COVID-19 in lungs, should be used as a first-line imaging modality in screening as well as for the following up of patients with COVID-19. HRCT is very sensitive in the diagnosis of COVID-19 infection in its milder forms. But it should not be used as a primary imaging tool/screening tool.

Limitation: Availability of a single CT scan machine and only a single CXR machine was a major limiting factor in our study as other machines were used for the rest of hospital indoor and out patients in order to

minimize the risk of cross-infection. The sample size was kept smaller due to this limiting factor.

References

1. Wong HY, Lam HY, Fong AH, Leung ST, Chin TW, Lo CS, Lui MM, Lee JC, Chiu KW, Chung T, Lee EY. Frequency and distribution of chest radiographic findings in COVID-19 positive patients. *Radiology*. 2020 Mar 27;201160. Wong HY, Lam HY, Fong AH, Leung ST, Chin TW, Lo CS, Lui MM, Lee JC, Chiu KW, Chung TW, Lee EY. Frequency and distribution of chest radiographic findings in patients positive for COVID-19. *Radiology*. 2020 Aug;296(2):E72-8.
2. Shi H, Han X, Jiang N, Cao Y, Alwalid O, Gu J, Fan Y, Zheng C. Radiological findings from 81 patients with COVID-19 pneumonia in Wuhan, China: a descriptive study. *The Lancet Infectious Diseases*. 2020 Feb 24. Shi H, Han X, Jiang N, Cao Y, Alwalid O, Gu J, Fan Y, Zheng C. Radiological findings from 81 patients with COVID-19 pneumonia in Wuhan, China: a descriptive study. *The Lancet infectious diseases*. 2020 Apr 1;20(4):425-34.
3. Yoon SH, Lee KH, Kim JY, Lee YK, Ko H, Kim KH, Park CM, Kim YH. Chest radiographic and CT findings of the 2019 novel coronavirus disease (COVID-19): analysis of nine patients treated in Korea. *Korean journal of radiology*. 2020 Apr 1;21(4):494-500. Yoon SH, Lee KH, Kim JY, Lee YK, Ko H, Kim KH, Park CM, Kim YH. Chest radiographic and CT findings of the 2019 novel coronavirus disease (COVID-19): analysis of nine patients treated in Korea. *Korean journal of radiology*. 2020 Apr 1;21(4):494-500.
4. Simpson S, Kay FU, Abbara S, Bhalla S, Chung JH, Chung M, Henry TS, Kanne JP, Kligerman S, Ko JP, Litt H. Radiological Society of North America Expert Consensus Statement on Reporting Chest CT Findings Related to COVID-19. Endorsed by the Society of Thoracic Radiology, the American College of Radiology, and RSNA. *Radiology: Cardiothoracic Imaging*. 2020 Mar 25; 2(2):e200152.
5. Durrani, M., Haq, I., Kalsoom, U. and Yousaf, A. (2020) "Chest X-rays findings in COVID 19 patients at a University Teaching Hospital - A descriptive study", *Pakistan Journal of Medical Sciences*, 36(COVID19-S4). DOI: 10.12669/pjms.36.COVID19-S4.2778 . Durrani M, Inam ul Haq UK, Yousaf A. Chest X-rays findings in COVID 19 patients at a University Teaching Hospital-A descriptive study. *Pakistan Journal of Medical Sciences*. 2020 May;36(COVID19-S4):S22.
6. Wong HY, Lam HY, Fong AH, Leung ST, Chin TW, Lo CS, Lui MM, Lee JC, Chiu KW, Chung T, Lee EY. Frequency and distribution of chest radiographic findings in COVID-19 positive patients. *Radiology*. 2020 Mar 27;201160. Wong HY, Lam HY, Fong AH, Leung ST, Chin TW, Lo CS, Lui MM, Lee JC, Chiu KW, Chung TW, Lee EY. Frequency and distribution of chest radiographic findings in patients positive for COVID-19. *Radiology*. 2020 Aug;296(2):E72-8.
7. Güneşli S, Atçeken Z, Doğan H, Altınmakas E, Atasoy KÇ. Radiological approach to COVID-19 pneumonia with an emphasis on chest CT. *Diagnostic and Interventional Radiology*. 2020 Jul; 26(4):323. Güneşli S, Atçeken Z, Doğan H, Altınmakas E, Atasoy KÇ. Radiological approach to COVID-19 pneumonia with an emphasis on chest CT. *Diagnostic and Interventional Radiology*. 2020 Jul;26(4):323.
8. Schiaffino S, Tritella S, Cozzi A, Carriero S, Blandi L, Ferraris L, Sardanelli F. Diagnostic performance of chest x-ray for COVID-19 pneumonia during the SARS-CoV-2 pandemic in Lombardy, Italy. *Journal of thoracic imaging*. 2020 Jul 1; 35(4):W105-6 . Schiaffino S, Tritella S, Cozzi A, Carriero S, Blandi L, Ferraris L, Sardanelli F. Diagnostic performance of chest x-ray for COVID-19 pneumonia during the SARS-CoV-2 pandemic in Lombardy, Italy. *Journal of thoracic imaging*. 2020 Jul 1;35(4):W105-6.
9. Nishtar T, Noor N, Khan SL. X-ray patterns of COVID-19 in patients presenting to Lady Reading Hospital, Peshawar, Pakistan. *Pakistan Journal of Medical Sciences*. 2021 Jan;37(1):28.
10. Li T, Han Z, Wei B, Zheng Y, Hong Y, Cong J. Robust Screening of COVID-19 from Chest X-ray via Discriminative Cost-Sensitive Learning. *arXiv preprint arXiv:2004.12592*. 2020 Apr 27. Li T, Han Z, Wei B, Zheng Y, Hong Y, Cong J. Robust screening of covid-19 from chest x-ray via discriminative cost-sensitive learning. *arXiv preprint arXiv:2004.12592*. 2020 Apr 27.
11. Wong HY, Lam HY, Fong AH, Leung ST, Chin TW, Lo CS, Lui MM, Lee JC, Chiu KW, Chung T, Lee EY. Frequency and distribution of chest radiographic findings in COVID-19 positive patients. *Radiology*. 2020 Mar 27;201160. Wong HY, Lam HY, Fong AH, Leung ST, Chin TW, Lo CS, Lui MM, Lee JC, Chiu KW, Chung TW, Lee EY. Frequency and distribution of chest radiographic findings in patients positive for COVID-19. *Radiology*. 2020 Aug;296(2):E72-8.
12. Ai T, Yang Z, Hou H, Zhan C, Chen C, Lv W, Tao Q, Sun Z, Xia L. Correlation of chest CT and RT-PCR testing in coronavirus disease 2019 (COVID-19) in China: a report of 1014 cases. *Radiology*. 2020 Feb 26;200642 . Ai T, Yang Z, Hou H, Zhan C, Chen C, Lv W, Tao Q, Sun Z, Xia L. Correlation of chest CT and RT-PCR testing for coronavirus disease 2019 (COVID-19) in China: a report of 1014 cases. *Radiology*. 2020 Aug;296(2):E32-40.
13. Cozzi D, Albanesi M, Cavigli E, Moroni C, Bindi A, Luvarà S, Lucarini S, Busoni S, Mazzoni LN, Miele V. Chest X-ray in new Coronavirus Disease 2019 (COVID-19) infection: findings and correlation with clinical outcome. *La Radiologia Medica*. 2020 Jun 9:1.
14. Giovagnoni A. Facing the COVID-19 emergency: we can and we do. *La Radiologia Medica*. 2020 Apr 3:1-2 Giovagnoni A. Facing the COVID-19 emergency: we can and we do. *Radiol Med*. 2020 Apr 1;125(4):337-8.
15. Rubin GD, Ryerson CJ, Haramati LB, Sverzellati N, Kanne JP, Raoof S, Schluger NW, Volpi A, Yim JJ, Martin IB, Anderson DJ. The role of chest imaging in patient management during the COVID-19 pandemic: a multinational consensus statement from the Fleischner Society. *Chest*. 2020 Apr 7.
16. Kaleemi R, Hilal K, Arshad A, Martins RS, Nankani A, Tu H, Basharat S, Ansar Z. The association of chest radiographic findings and severity scoring with clinical outcomes in patients with COVID-19 presenting to the emergency department of a tertiary care hospital in Pakistan. *PLoS One*. 2021 Jan 5;16(1):e0244886.
17. Khan SA, Manohar M, Khan M, Asad S, Adil SO. Radiological profile of patients undergoing Chest X-ray and computed tomography scans during COVID-19 outbreak. *Pakistan Journal of Medical Sciences*. 2021 Sep;37(5):1288.