

Effectiveness of various treatment strategies in COVID-19 patients having Solid Organ Transplant: A Systematic Review

Muhammad Shehryar Hussain¹, Khadeja Farrukh², Tehniyat Iqbal³, Aleeza Fatima⁴, Zunira Mughis⁵,
Hafiz Amjad Hussain⁶

¹ 4th Year MBBS student, Allama Iqbal Medical College, Lahore.

² 3rd Year MBBS student, Fatima Jinnah Medical University, Lahore.

³ 4th Year MBBS student, Fatima Jinnah Medical University, Lahore.

⁴ 3rd Year MBBS student, Services Institute of Medical Sciences, Lahore.

⁵ Mphil Microbiology, University of Veterinary & Animal Sciences, Lahore.

⁶ Assistant Professor, Department of Medicine, Faisalabad Medical University, Faisalabad.

Author's Contribution

^{1,2,3,4,6} Conception of study

^{1,2,3,4,5,6} Experimentation/Study conduction

^{1,2,3,4,5,6} Analysis/Interpretation/Discussion

^{1,2,3,4,5} Manuscript Writing

^{1,2,3,4,5,6} Critical Review

Corresponding Author

Dr. Muhammad Shehryar Hussain

4th Year MBBS student,

Allama Iqbal Medical College,

Lahore

Email: shehryar1032@gmail.com

Article Processing

Received: 20/05/2021

Accepted: 30/08/2021

Cite this Article: Hussain, M.S., Farrukh, K., Iqbal, T., Fatima, A., Mughis, Z, Hussain, H.A. Effectiveness of various treatment strategies in COVID-19 patients having Solid Organ Transplant: A Systematic Review. *Journal of Rawalpindi Medical College*. 31 Aug. 2021; 25 COVID-19 Supplement-1, 138-148. DOI: <https://doi.org/10.37939/jrmc.v25i1.1668>

Conflict of Interest: Nil
Funding Source: Nil

Access Online:



Abstract

Introduction: This narrative review provides an evidence-based summary of the various interventions in the management of Post Solid organ transplant patients who reported positive for COVID-19.

Materials and Methods: For this systematic review, observational and experimental studies; conducted on Post-Organ transplant patients, either symptomatic or asymptomatic, who tested positive for COVID-19 were included. Only solid organ transplant patient studies were considered standard for this review type. The English version, both published and unpublished articles, from Dec 2019 to Aug 2020, were evaluated using Pubmed, Google Scholar, Science direct, Medrxiv search engines. The articles with incomplete details about a transplant or covid management were excluded.

Results: We selected 43 articles out of which 9 were retrospective studies, 2 were cohort studies, one was an experimental study, and 31 were case studies. According to the literature review, effective management therapy includes the withdrawal of immunosuppressive drugs, increase/ constant steroid dose, and regimen containing HCQ, interleukin inhibitor, and one antiviral drug especially remdesivir proved to be the most effective among all. In others, administration of IV immunoglobulins/convalescent plasma therapy proved effective in various trials but related data is currently limited. While Lop/Rit, Interferons alpha, and oseltamivir trials are also given; these therapies didn't prove to be much effective individually.

Conclusion: More trials are required to find the effectiveness of Convalescent plasma therapy. It can be proved as an effective treatment in critical patients. IV immunoglobulins effectiveness should also be tested in critical patients and for this more experimental trials are needed.

Keywords: COVID-19 treatment, organ transplant patient, management of COVID-19, solid organ transplant patients; effectiveness of various treatments in SARS-CoV-2.

Introduction

In early December 2019, coronavirus disease rapidly swept across Wuhan, China. Due to its widespread transmission, it was declared a pandemic by WHO in January 2020.¹ As this pandemic maintains to spread, statistics on the scientific characteristics and consequences of COVID-19 are emerging throughout continents.² The novel coronavirus has been found strikingly similar to the virus which causes severe acute respiratory syndrome (SARS) in its morphology.^{3,4} The symptoms of COVID-19 vary but commonly fever, dry cough, fatigue and, generalized weakness have been observed.⁵

Our study is based on how COVID-19 manifests in patients with solid organ transplants. By analyzing data from 2008 for 104 countries, every year 100800 solid organ transplants are performed worldwide: 69400 are kidney transplants, 20200 are liver transplants, 3400 are lung transplants, 2400 are pancreas transplants and 5400 are heart transplants. The clinical findings, therapeutic approach, and consequences of COVID-19 in patients with solid organ transplants remain unknown.⁶ We collected data from different databases to conclude how COVID-19 manifests in patients with solid organ transplants and how we can manage its progression and immunosuppression via effective treatment options.

Materials and Methods

The eligibility criterion of our study was researches related to COVID-19 management in solid organ transplant patients. We searched four databases PubMed, Google scholar, science direct, and medrxiv for our systematic review from December 2019 till August, 2020. Original articles, retrospective studies, and case studies in English were selected. Search terms used were: COVID-19 treatment in organ transplant patients, management of COVID-19 in solid organ transplant patients, and effectiveness of various treatments in COVID-19 patients with organ transplants.

Four reviewers reviewed the database separately. In the first step, articles were excluded based on the title. Those studies were excluded which were not related to the management of COVID 19 in organ transplant patients. In the second step, duplicate articles and articles based on abstract were removed. All the articles other than original, retrospective and case studies were excluded. In the third step, full-text

articles were assessed and articles based on quality and incomplete data were removed. Articles with ambiguous information were reviewed by more than one author and then excluded after the final discussion. All studies based on experiments on animals, artificial intelligence, editorials, comments of authors were excluded. Articles in a language other than English were also excluded. Data were extracted by four authors individually and finally reviewed by one author. Data were extracted based on variables which include study type, number of patients, time since organ transplant, COVID-19 symptoms, and management of covid19 patients in organ transplant patients.

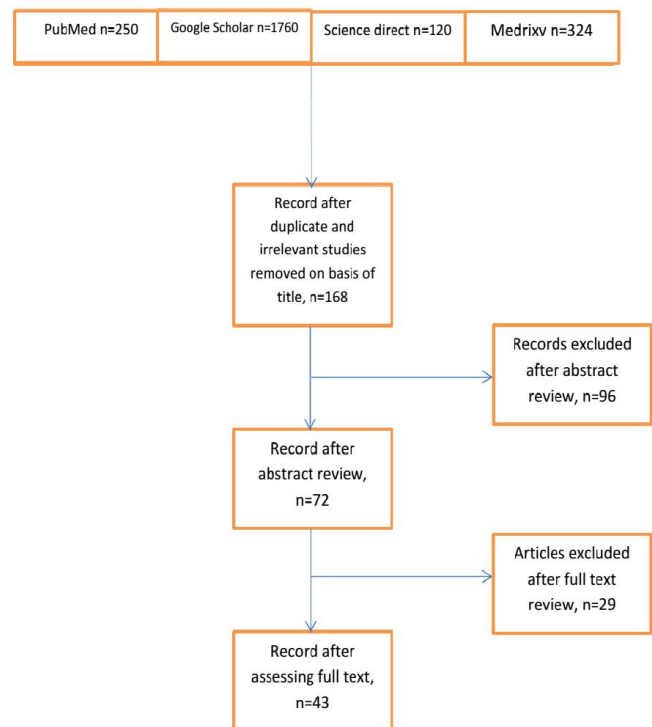


Figure 1:

Results

For this systematic review, we searched four research engines. Out of 2454 articles initially acquired, only 43 were selected in the final review based on the inclusion and exclusion criteria. Among these 43 articles: 9 were retrospective studies, 2 were cohort studies, and 31 were the case series. We extracted the respiratory complications and management of Covid-19 from these articles in the form of a table. We made a column for “Covid-19 respiratory complications” in which we mentioned all the changes that were observed in the lungs of the patient during the

progression of covid-19. “Covid-19 specific treatment column” represented the treatment strategies used by health care professionals specifically against covid-19. The next column was “management of immunosuppression in Covid-19 patients”, which represented the changes made in patient organ transplant immunosuppression regime while treating a patient for Covid-19. In the end, “outcome” represented the final result whether the patient survived or not. Either the patient is discharged or still hospitalized was also mentioned in this column. The results of COVID-19 treatment and immunosuppressive management have been summarized in the following sections:

Covid-19 in Renal Transplant patients:

Data retrieved from case reports and retrospective studies suggest that kidney transplant patients with an average age of 50, normally presented with fever, cough, and malaise and later on developed respiratory complications. Almost all of them had comorbidities but no association was found between them and the progression of COVID-19. Patients recovered with symptomatic treatment along with temporary amendments in the immunosuppressive regimen. COVID-19 specific and immunosuppression management in renal transplant patients is discussed in Table 1.

Table 1: Management of COVID-19 in a patient with Renal transplants

Author	COVID-19 respiratory complications	COVID-19 specific treatment	Management of Immunosuppression in covid-19	Outcome
F. Fontana et al. ⁷	Bilateral basal interstitial pneumonia	HCQ (200 mg) bid IV Fluids, Tocilizumab (324 mg) S/C , IVIG (0.3 g/kg dose)	CyA withdrawn, oral steroid dose increased (methylprednisolone 16 mg per day)	Discharged home on day 22
A. Lauterio et al. ⁸	First Unilateral then Bilateral subpleural GGO consolidation, Intralobular septal thickening	Lop/Rit (400mg/100mg BID), HCQ (400mg BID), Broad spectrum Antibiotics, LMW heparin ,I/V tocilizumab (Single Dose)	CSA and were withdrawn, while PRED was increased to 40 mg daily.	The patient was discharged on D50
L. Zhu et al. ⁹	Bilateral multiple patchy ground-glass densities	Umifenovir, IVIG, Biapenem; Pantoprazole (QD); Interferon α (5 million units daily, atomization inhalation)	D/C all ISx, Methylprednisolone daily I/V, Oral Tac resumed 1/2 dose after 5 days D11 oral TAC & MMF to their full pre-illness dosage levels	Discharged (day 13 of hospital administration)
S. Meziyerh et al. ¹⁰	Peripherally localized consolidations in multiple lobes progressed to bilateral consolidation	oral chloroquine, Lopinavir/Ritonavir; 5 L of oxygen therapy through the nasal cannula.	everolimus dose was reduced later discontinued.	Discharged
T. Thammathiwat et al. ¹¹	Bilateral multifocal patchy infiltration	Darunavir, ritonavir, hydroxychloroquine, azithromycin, and favipiravir, IV Immunoglobulin	TAC MMF was discontinued. MMF was recontinued after treatment	Alive

C. Q. Santos et al. ¹²	viral pneumonia in Chest radiographs- 8/11	Hydroxychloroquine 2/14 Tocilizumab 1/14 High-dose glucocorticoids 2/14 Remdesivir 1/14	Withdrawal of calcineurin inhibitor 3/13 Withdrawal of antimetabolite 10/12 Withdrawal of mTOR inhibitor 2/2	Death 2/14
F. Silva et al. ¹³	Bilateral interstitial infiltrate 2/5 Multifocal GGO 2/5	HCQ 3/5 No specific treatment 2/5	MMF suspension 4/5, AZA & CyA suspension 1/5 Reduction in TAC 3/5	Discharged 4/5 Death 1/5
M. Lubetzky et al. ¹⁴	Viral pneumonia diagnosis 36/42	HCQ 32(62%) Remdesivir 2(4%) IL-6 receptor inhibitor 2(4%), Convalescent plasma 1(2%)	Tac reduction 17(33%) , MMF reduction 15(28%) held 24(44%) Additional steroid therapy 5(9%)	7 pt. died
Ghaffari et al. ⁴⁵	Bilateral lung involvement with GGO/consolidation, pericardial or pleural effusion	oseltamivir, HCQ, lop/rit, ribavirin, favipiravir, convalescent plasma therapy, IVIG	MMF/MPA discontinued, CNI dose reduced	10 survived, 9 died
Zhu et al. ⁴⁶	Bilateral lobular consolidation, patchy GGO, pulmonary lesions	Umifenovir, oseltamivir, ribavirin, ganciclovir	CNIs reduced/ discontinued, methyl pred cont.	9 survived, 1 died
Abrishami et al. ⁴⁷	Uni/Bilateral lung GGO & consolidation, pleural & pericardial effusion	HCQ, lop/Rit, suitable IV antibiotics, IVIG	Doses reduced	4 survived, 8 died
Nair et al. ⁴⁸	Multifocal patchy opacities	HCQ, azithromycin	Antimetabolites stopped, Tac dec.	8 survived, 3 died
Huang et al. ³⁶	N/A	Oseltamivir, moxifloxacin, methyl pred	N/A	Died
Guillen et al. ³⁴	medium lobe consolidation	Azithromycin, Lopinavir, HCQ, Interferon Beta, HCV	Tac, everolimus stopped.	Survived
Devreese et al. ²⁶	N/A	HCQ	MMF stopped, TAC/ CyA, EVL dose reduced.	Recovered 13, died:2, hospitalized 3
Zhong et al. ³¹	BL flocculent fuzzy lesions.	oseltamivir, abidol, moxifloxacin, interferon-alpha, Methylpred, IVIG	MMF suspended	Survived
Seminari et al. ³⁰	Interstitial lesions	NIL	unchanged	Survived

Covid-19 in Lung Transplant patients

Four case studies were screened for progression of COVID-19 in lung transplant patients. Average time since transplant was found to be 36 months. Patients

with an average age of 53 years usually presented with fever and cough. Most of them developed respiratory complications and required oxygen support. One of the patients developed graft dysfunction leading to

death due to COVID-19 complications and secondary bacterial infection. Patients with different immunosuppressive therapy presented with different severity of disease which is suggestive of the fact that immunosuppressive regimen; especially steroids may play their part in the progression of the disease. In

nearly all of the patients with symptomatic disease, immunosuppressive therapy was altered while no change was made in the regimen for patients without any symptoms. Covid-19 specific and immunosuppression management in lung transplant patients is discussed in (Table 2).

Table 2: Management of COVID-19 inpatient with LUNG transplant

Author	Covid Complications	COVID-19 specific treatment	Immunosuppression management	Outcome
L. Morlacchi et al. ¹⁵	Typical patchy bilateral GGO 3/4, Patchy unilateral GGO 1/4	HCQ + methylprednisolone 4/4 Anakinra and remdesivir 1/4	AZA withhold	Discharged 3/4 Died 1/4
Rembert A koczulla et al. ¹⁶	X-ray showed no infiltrates	Not specific	No change	Discharged
N. Desmazes-Dufeu et al. ¹⁷	GGO in lower lobes & subpleural linear consolidations 1/2	N/A	Mycophenolate was discontinued & MMF was restarted after discharge	Discharged 2/2
Myers et al. ²⁵	bilateral ground-glass opacities	Remdesivir, Anakinra, Tocilizumab	methylpred, IVIG, Nucleotide-blocking agent held(n: 6), No change:(n:2)	died: 2 Survived:6
Cozzi et al. ²⁷	GGO	Pt1: nil Pt2: lopinavir/ritonavir, azithromycin	pt1:MMF stopped. pt2: Tac, MFF stopped	pt1: survived pt2: died

Covid-19 in Heart Transplant patients

Studies suggest that patients with heart transplants; median age 56 years presented with common symptoms of COVID-19: fever, dry cough, and GIT disturbances. One retrospective study and four case studies were extracted. Nearly all of the patients were hypertensive and their antihypertensive treatment was

continued along with reduced immunosuppressive therapy. Patients who did not survive usually presented with worsening symptoms and required intubation. The modifications in immunosuppression and COVID-19 specific treatment have been presented in Table 3.

Table 3: Management of COVID-19 inpatient with Heart transplant

Author	COVID-19 respiratory complications	COVID-19 specific treatment	Immunosuppression management	Outcome
G. Vaidyaa et al. ¹⁸	Bilateral lung infiltrates, worsening pneumonia	clazakizumab (anti-IL-6) 25 mg in 50 mL normal saline, given over 30 minutes.	MMF discontinued. TAC dose decreased	Discharged on day 11
Ahluwalia et al. ³⁷	Oxygen saturation less than 94	Remdesivir(3D)	MMF held, CNI reduced, methylprednisone	4 recovered, 1 died
Scott W. et al. ³⁸	Bilateral pulmonary infiltrates	Tocilizumab, corticosteroids	HCQ, TAC reduced, MMF discontinued	11 survived, 2 died
Iacovoni et al. ³⁹	Severe pneumonia and low oxygen saturation	HCQ, ritonavir/lopinavir, Enoxaparin	EVL & MMF discontinued, Tac/ CyA continued oral methyl pred Cont.	19 survived, 7 died

Singhvi et al. ⁴⁰	Multifocal opacities on chest radiographs	HCQ, azithromycin, tocilizumab, remdseivir, plasma, glucocorticoids	CNIs not modified, mTORi and antimetabolites held and reduced	17 survived, 5 died
Decker et al. ²²	NIL	HCQ	Pred increased and adjusted several times.	CsA survived

Covid-19 in multiple transplant patients

There are 2 case reports, one with kidney-liver transplant and the other with the kidney-pancreas transplant. The intensity of the disease is not affected by the time of transplant in any study. The maintenance of immunosuppressive treatment is according to the severity of Covid-19. Fever, cough,

and shortness of breath are disclosed as common symptoms. Diabetes and hypertension are common in these patients. ARBs and B-blockers are used by and large to treat comorbidities. Covid-19 specific and immunosuppression management in multiple transplant patients is discussed in Table 4.

Table 4: Management of COVID-19 inpatient multiple organ transplant

Author	COVID-19 respiratory complication	COVID-19 specific treatment	Immunosuppression management	Outcome
Antony et al. ⁴¹	GCO and pneumothorax	HCQ, tocilizumab, coalescent plasma.	MPA and Tac discontinued, methyl pred administered	survived
Suwanwongse et al. ²¹	BL GGO	HCQ.	TAC stopped.	died

Covid-19 in Liver Transplant patient

There are 5 case reports about patients with liver transplants. There is no significant impact of time of transplant on the severity of Covid-19. Most of the studies find fever, cough, fatigue, and headache as general symptoms. All patients were previously on immunosuppression treatment which was managed according to the intensity of covid-19 in them.

Hepatitis B, Jaundice, splenomegaly, diabetes, and hypertension are reported as common comorbidities and are effectively treated. Covid-19 specific and immunosuppression management in liver transplant patients is discussed in Table 5.

Table 5: Management of COVID-19 inpatient with Liver transplant

Author	Covid19 respiratory complications	Covid19 specific treatment	Immunosuppression management	outcome
Modi et al. ²⁹	NIL	HCQ	MMF stopped. Tac dec.	survived
Hammami et al. ²⁸	GGO	AZM, HCQ, tocilizumab,	N/A	survived
Zhong et al. ³¹	Bilateral patchy GGO	Oseltamivir phosphate	Tac suspended	survived
Huang et al. ³²	BL ground-glass opacities	αinterferon, lopinavir/ritonavir, methylpred	Tac, MMF halved	Died
De Gottardi et al. ³³	BL subpleural GGO	Lopinavir, HCQ	Sirolimus decreased	survived

Covid-19 in Variable Transplant patients

There are 2 case reports, 4 retrospective studies, 1 experimental study, and 1 cohort study. Fatigue, myalgia, and fever are described as general symptoms in most of the studies. The regime of patients is

modified according to the degree of infection and the condition of the immune system. Diabetes, hypertension, CVDs, and cirrhosis are outlined as common comorbidities. ARBs, ACE-i, and insulin are repeatedly used to treat comorbidities. Covid-19

specific and immunosuppression management in variable transplant patients is discussed in Table 6.

Table 6: Management of COVID-19 inpatient with solid organ transplant (variable)

Author	Type of transplant	COVID-19 respiratory complications	COVID-19 specific treatment	Immunosuppression management	Outcome
Kates et al. ⁴²	Multifocal infiltrates on X-ray	Multifocal infiltrates on X-ray	HCQ, oxygen supplementation	MMF held, Tac reduced, PRED added, ARB held, empirical antibiotics	Survived
	NIL	NIL	Supportive care	No change	Survived
	NIL	NIL	Supportive care	No change	Survived
Funget et al. ⁴³	bilateral GGO & consolidations	bilateral GGO & consolidations	Immunosuppressive therapy decreased	No change	Survived
Fernandez Ruiz et al. ⁴⁴	NIL	NIL	Lop/rit, HCQ	Reduction of tac, D/C MPA, pred	6 survived, 2 died
	NIL	NIL	Lop/rit, HCQ	Converted from EVE to Tac and MMF	4 survived, 2 died
Pereira et al. ³⁵	SOB	SOB	HCQ, Lop/rit, IFN- beta	D/C cyA	3 survived, 1 died
	Bilateral opacities.	Bilateral opacities.	HCQ, Azithromycin, Remdesivir, steroids, Tocilizumab	Antimetabolite, steroids, CNI dec or held.	died: 16 discharged: 37 still hospitalized: 15
HOEK et al. ²⁴	The radiograph showed viral pneumonia.	The radiograph showed viral pneumonia.	HCQ:3 No specific: 9 Azithromycine: 11	No change :13 MMF or ERL dec: 10	died: 5, discharged: 14, recovering: 4
Yi et al. ²³	GGO with multilobar involvement (n: 10)	GGO with multilobar involvement (n: 10)	HCQ, azithromycin, Remdesivir, Convalescent plasma therapy, Tocilizumab, interferonalph, Anakinra	Antimetabolite held: 12 CNI reduced: 3 Increased steroids: 3	Died: 1 Discharged: 8 Remains hospitalized :6
Matthew B. Roberts et al. ¹⁹	Unilateral 5 (16%) Bilateral 17 (53%) None 10 (31%)	Unilateral 5 (16%) Bilateral 17 (53%) None 10 (31%)	For 32 indoor patients HCQ 11 Pt. (35%); Statins 21 (68%), Tocilizumab 1(3%) Remdesivir 1(3%) Supplemental oxygen 23(72%); prone positioning 9(28%) vasopressor required 11(34%)	ISx changed 22 (69%) ; MMF/AZA recipients 19 (71%) held (50%) or reduced (29%). CNI in 1 (4%); mTOR inhibitors held 3 (100%); Belatacept deferred in 2 out of 3 patients	23 (72%) discharged; Five (16%) died; 4 (36%) still hospitalized

C. Loinaz et al. ²⁰	Lung infiltrates in 13 Pt. (68.4%); bilateral in 12 of them (63.1%).	Lung infiltrates in 13 Pt. (68.4%); bilateral in 12 of them (63.1%).	HCQ 11/19; Lop/rit 2/19 IFN-b 2/19 TCZ 2/19 No Sp. treatment (7/19)	Reduced MMF in 2/19 EVE in 2 /19 No change 16/19	the patient died (2); rest were discharged
--------------------------------	--	--	--	--	--

There is solid evidence that management of immunosuppressive therapy in SOT patients stays the focal point of COVID-19 treatment. In all of the SOT patients who presented with COVID-19 complications, immunosuppressive therapy was transiently modified, usually halted or reduced. Many times this alone proved effective. HCQ proved to be the mainstay of COVID- specific treatment. Azythromycin was synergistically used along HCQ in lowering a viral load. Among antivirals, remdesivir was most competently used and it proved productive whereas lopinavir/ritonavir didn't prove to be effective. Interleukin inhibitor, Tocilizumab was frequently used however nothing at this point can be predicted about its efficacy. Scarce evidence is available on the use of convalescent plasma therapy, however, in some critical cases, it proved to be the life-saving option. The most effective management therapy in severe cases includes the withdrawal of immunosuppressive drugs, increase/ constant steroid dose and regimen containing HCQ, interleukin inhibitor, and one antiviral drug especially remdesivir..

Additional Recommendations

COVID-19 has been considered lethal for patients who have gone through a solid organ transplant. However, our retrieved data suggests that decreasing the immunosuppression regimen and increasing the steroids along with an appropriate dose of COVID-19 specific medicines can result in 70 to 80 percent efficacy.

Antivirals like remdesivir have shown positive results which may be due to their relatively non-toxic effects and less drug-drug interaction. The use of lop/rit for treating COVID-19 has been discouraged by recent studies. In a case report by Jiao-Feng et al. lop/rit treatment of a patient with a liver transplant resulted in multiple organ failure and mortality.⁴⁹ Hydroxychloroquine combined with lop/rit must be keenly tracked due to their known hepatotoxic effects.⁵⁰ Data from different studies reveal that hydroxychloroquine can be looked after as a potential

treatment option for COVID-19. However, according to a recent study, Hydroxychloroquine along with azithromycin can adversely affect the cardiac conduction pathways leading to arrhythmias so it is advisable to closely monitor the ECGs of patients especially if they have cardiac comorbidities.⁵¹

The use of interleukin blockers like tocilizumab as a treatment option for COVID-19 is based on the belief that interleukins, especially interleukin-6, are the inflammatory substance resulting in lung damage. However, in a case series by Marcus R et al. the mortality rate of organ transplant patients who received tocilizumab was significantly higher than the patients who were treated without tocilizumab.⁵² Therefore, building a shred of strong evidence about interleukin blockers as a possible treatment option for Covid-19 demands more studies.

The emergence of COVID-19 has also reevaluated the effectiveness of historic convalescent plasma transfusion (CPT) which may reduce the mortality rate in critically ill patients. There is only a shred of the limited evidence available on it till now and multiple clinical trials are still ongoing. The convalescent plasma (CP) strategy is currently being used for prophylaxis as well as for the treatment of contagious diseases since the early 20th century.⁵³ Apheresis is the procedural methodology to obtain blood plasma, based on continuous centrifugation of blood from donors (who are potentially recovered from the disease).⁵⁴ A study by Shen et al showed 5 critically ill SARS CoV 2 infected patients reculant to antivirals, received Convalescent plasma therapy. After transfusion the fever settled down within 3 days, PaO₂/FiO₂ raised and PCR became negative within 12 days.⁵⁵ Another study conducted by Duan et al. showed the results from 10 severe cases who received one dose of CP leading to the disappearance of viremia in 7 days and clinical symptoms readily improved within 3 days.⁵⁶ Thus, the administration of convalescent plasma is a potentially effective strategy with promising evidence on the improvement of clinical symptoms and with no side effects reported till now.

IVIg; a pooled normal IgG having both immunomodulation and immune substitution effects, is obtained from the blood of healthy donors.⁵⁷ It can elicit passive immunity and is an ideal option for the management of COVID patients. IVIG is considered to target cytokine storms in severe COVID-19 patients. In a study, Mohtadi et al reported five critically ill SARS-CoV 2 infected patients for whom IVIG was administered, which prevented the further downturn of symptoms. A high-dose IVIG (0.3–0.5 g/kg) was given to all patients for consecutive five days. Overall the patients' response was satisfactory and they were discharged from the hospital after complete recovery.⁵⁸ Another study by Cao et al reported 3 patients with critical Covid-19 conditions. They were given high-dose intravenous immunoglobulin (IVIg). They also recovered promptly and were discharged.⁵⁹ Keeping in mind its potency in modulating immune inflammation high-dose IVIg could be considered an encouraging alternative at the initial stage of the clinical downturn of patients with COVID-19. Further experiments should be conducted to infer the effectiveness of this approach.

Limitations of this study include that up till now a finite number of studies have been conducted on the management of SARS-CoV 2 disease in organ transplant patients. We excluded articles of all languages except English. We considered only the Solid-organ type of transplant, other types of transplant articles are not considered. Limited data of patients were available as most of the case report studies were found. Thus, more experiments are still required to assess the potency of different management strategies in Solid organ transplant patients with CoV disease.

Conclusion

To sum up, in organ transplant patients with covid-19, withdrawal of immunosuppressive drugs revealed considerably good results. Hydroxychloroquine manifested results up to the mark. But Lopinavir and Ritonavir were found to be non-productive. Intravenous Immunoglobulin and Convalescent plasma therapy were also used. Amidst all medicinal techniques, convalescent plasma transfusion is found to be a potentially effective strategy. But multiple clinical trials are still required to infer the efficacy of this treatment.

References

1. Wang, D. et al. Clinical characteristics of 138 hospitalized patients with 2019 novel coronavirus-infected pneumonia in Wuhan, China. *JAMA* <https://doi.org/10.1001/jama.2020.1585> (2020)
2. Pneumonia of unknown cause — China: disease outbreak news. Geneva: World Health Organization, January 5, 2020 (<https://www.who.int/csr/don/05-january-2020-pneumonia-of-unknown-cause-china/en/>).
3. Huang C, Wang Y, Li X, et al. Clinical features of patients infected with 2019 novel coronavirus in Wuhan, China. *Lancet*. 2020; 395(10223):497-506.
4. Porcheddu R, Serra C, Kelvin D, et al. Similarity in case fatality rates (CFR) of COVID-19/SARS-COV-2 in Italy and China. *J Infect Dev Ctries*. 2020; 14(2):125-128.
5. H. Shi, X. Han, N. Jiang, Y. Cao, O. Alwalid, J. Gu, Y. Fan, C. Zheng, Radiological findings from 81 patients with COVID-19 pneumonia in Wuhan, China: a descriptive study, *Lancet Infect Dis*. 20 (2020) 425-434.
6. Michaels MG, La Hoz RM, Danziger-Isakov L, et al. Coronavirus disease 2019: implications of emerging infections for transplantation. *Am J Transplant*. [published online ahead of print 2020]. <https://doi.org/10.1111/ajt.15832>.
7. Fontana F, Alfano G, Mori G, Amurri A, Lorenzo T, Ballestri M, et al. Covid-19 pneumonia in a kidney transplant recipient successfully treated with Tocilizumab and Hydroxychloroquine. *Am J Transplant*. 2020;2:0–3.
8. Lauterio A, Valsecchi M, Santambrogio S, De Carlis R, Merli M, Calini A, et al. Successful recovery from severe COVID-19 pneumonia after kidney transplantation: The interplay between immunosuppression and novel therapy including tocilizumab. *Transpl Infect Dis*. 2020;e13334.
9. Zhu L, Xu X, Ma K, Yang J, Guan H, Chen S, et al. Successful recovery of COVID-19 pneumonia in a renal transplant recipient with long-term immunosuppression. *Am J Transplant*. 2020;20(7):1859–63.
10. Meziyerh S, Zwart TC, van Eften RW, Janson JA, van Gelder T, Alwayn IPJ, et al. Severe COVID-19 in a renal transplant recipient: A focus on pharmacokinetics. *Am J Transplant*. 2020;20(7):1896–901.
11. Thammathiwat T, Tungsanga S, Tiankanon K, Torvorapanit P, Chumpangern W, Udomkarnjananun S, et al. A Case of Successful Treatment of Severe COVID-19 Pneumonia with Favipiravir and Tocilizumab in Post-kidney Transplant Recipient. *Transpl Infect Dis*. 2020;e13388.
12. Q Santos CA, Rhee Y, Hollinger EF, Olaitan OK, Schadde E, Peev V, et al. Title: Comparative Incidence and Outcomes of COVID-19 in Kidney or Kidney-Pancreas Transplant Recipients Versus Kidney or Kidney-Pancreas Waitlisted Patients: A Pilot Study. *medRxiv* [Internet]. 2020;2020.07.20.20157990. Available from: <https://www.medrxiv.org/content/10.1101/2020.07.20.20157990v1%0Ahttps://www.medrxiv.org/content/10.1101/2020.07.20.20157990v1.abstract>
13. Silva F, Cipriano A, Cruz H, Tavares J, Fragoso J, Malheiro J, et al. SARS-CoV-2 infection in kidney transplant recipients: Early report of five cases. *Transpl Infect Dis*. 2020;(May):1–7.
14. Lubetzky M, Aull M, Craig-Shapiro R, Lee JJ, Lee JJ, Sultan S, et al. Kidney Allograft Recipients Diagnosed with Coronavirus Disease-2019: A Single Center Report. *medRxiv* [Internet]. 2020;2020.04.30.20086462. Available from: <http://medrxiv.org/lookup/doi/10.1101/2020.04.30.20086462>

15. Morlacchi LC, Rossetti V, Gigli L, Amati F, Rosso L, Aliberti S, et al. COVID-19 in lung transplant recipients: A case series from Milan, Italy. *Transpl Infect Dis.* 2020;
16. Koczulla RA, Sczepanski B, Koteczki A, Kuhnert S, Hecker M, Askevold I, et al. SARS-CoV-2 infection in two patients following recent lung transplantation. *Am J Transplant.* 2020;0-1.
17. Desmazes-Dufeu N, Coltey B, Amari L, Gouitaa M, Touzery C, Reynaud-Gaubert M, et al. Discordant courses of COVID-19 in a cohabiting couple of lung transplant recipients. *Transpl Infect Dis.* 2020;(July):1-5.
18. Vaidya G, Czer LSC, Kobashigawa J, Kittleson M, Patel J, Chang D, et al. Successful Treatment of Severe COVID-19 Pneumonia With Clazakizumab in a Heart Transplant Recipient: A Case Report. *Transplant Proc [Internet].* 2020;1(310):10-3. Available from: <https://doi.org/10.1016/j.transproceed.2020.06.003>
19. Roberts MB, Izzy S, Tahir Z, Al Jarrah A, Fishman JA, El Khoury J. COVID-19 in solid organ transplant recipients: dynamics of disease progression and inflammatory markers in ICU and non-ICU admitted patients. *Transpl Infect Dis.* :e13407.
20. Loinaz C, Marcacuzco A, Fernández-Ruiz M, Caso O, Cambra F, San Juan R, et al. Varied clinical presentation and outcome of SARS-CoV-2 infection in liver transplant recipients: initial experience at a single center in Madrid, Spain. *Transpl Infect Dis.* 2020;e13372.
21. Suwanwongse K, Shabarek N. Fatal Outcome in a Kidney-Pancreas Transplant Recipient With COVID-19. *Cureus.* 2020;12(6).
22. Decker A, Welzel M, Laubner K, Grundmann S, Kochs G, Panning M, et al. Prolonged SARS-CoV-2 shedding and mild course of COVID-19 in a patient after recent heart transplantation. *Am J Transplant.* 2020;
23. Yi SG, Rogers AW, Saharia A, Aoun M, Faour R, Abdelrahim M, et al. ACE inhibitors. *Transplantation.* 2020;Publish Ah(Xxx):1-7.
24. Hoek RAS, Manintveld OC, Betjes MGH, Hellemons ME, Seghers L, Van Kampen JAA, et al. COVID-19 in solid organ transplant recipients: a single-center experience. *Transpl Int.* 2020;
25. Myers CN, Scott JH, Criner GJ, Cordova FC, Mamary AJ, Marchetti N, et al. COVID-19 in Lung Transplant Recipients. *Transpl Infect Dis.* 2020;(May):1-5.
26. Devresse A, Belkhir L, Vo B, Ghaye B, Scohy A, Kabamba B, et al. COVID-19 Infection in Kidney Transplant Recipients: A Single-Center Case Series of 22 Cases From Belgium. *Kidney Med.* 2020;
27. Cozzi E, Faccioli E, Marinello S, Loy M, Congedi S, Calabrese F, et al. COVID-19 pneumonia in lung transplant recipients: report of two cases. *Am J Transplant.* 2020;
28. Hammami MB, Garibaldi B, Shah P, Liu G, Jain T, Chen PH, et al. Clinical Course of COVID-19 in a Liver Transplant Recipient on Hemodialysis and Response to Tocilizumab Therapy: A Case Report. *Am J Transplant.* 2020;0-2.
29. Modi AR, Koval CE, Taeye AJ, Modaresi Eseh J, Egtesad B, Narayanan Menon K V., et al. Coronavirus disease 2019 in an orthotopic liver transplant recipient living with human immunodeficiency virus. *Transpl Infect Dis.* 2020;(May).
30. Seminari E, Colaneri M, Sambo M, Gallazzi I, Di Matteo A, Roda S, et al. SARS Cov-2 infection in a renal-transplanted patient: A case report. *Am J Transplant.* 2020;
31. Zhong Z, Zhang Q, Xia H, Wang A, Liang W, Zhou W, et al. Clinical characteristics and immunosuppressant management of coronavirus disease 2019 in solid organ transplant recipients. *Am J Transplant.* 2020;20(7):1916-21.
32. Huang JF, Zheng KI, George J, Gao HN, Wei RN, Yan HD, et al. Fatal outcome in a liver transplant recipient with COVID-19. *Am J Transplant.* 2020;20(7):1907-10.
33. De Gottardi A, Fratila C, Bertoli R, Cerny A, Magenta L, Gianella P, et al. Clinical characteristics and management of a liver transplanted patient admitted with SARS-CoV-2 infection. *Clin Res Hepatol Gastroenterol [Internet].* 2020;4-7. Available from: <https://doi.org/10.1016/j.clinre.2020.05.014>
34. Guillen E, Pineiro GJ, Revuelta I, Rodriguez D, Bodro M, Moreno A, et al. Case report of COVID-19 in a kidney transplant recipient: Does immunosuppression alter the clinical presentation? *Am J Transplant.* 2020;20(7):1875-8.
35. Pereira MR, Mohan S, Cohen DJ, Husain SA, Dube GK, Ratner LE, et al. COVID-19 in solid organ transplant recipients: Initial report from the US epicenter. *Am J Transplant.* 2020;
36. Huang J, Lin H, Wu Y, Fang Y, Kumar R, Chen G, et al. COVID-19 in posttransplant patients—report of 2 cases. *Am J Transplant.* 2020;20(7):1879-81.
37. Ahluwalia M, Givertz MM, Mehra MR. A Proposed Strategy for Management of Immunosuppression in Heart Transplant Patients with COVID-19. *Clin Transplant.* 2020;
38. Sonja A. Rasmussen, MD, MS JCS, Wang J, Li X, Cao G, Wu X, Wang Z, et al. Since January 2020 Elsevier has created a COVID-19 resource centre with free information in English and Mandarin on the novel coronavirus COVID-. *Ann Oncol.* 2020;(January):19-21.
39. Iacovoni A, Boffini M, Pidello S, Simonato E, Barbero C, Sebastiani R, et al. A case series of Novel-Coronavirus infection in heart transplantation from two centers in the pandemic area in the North of Italy. *J Hear Lung Transplant.* 2020;
40. Singhvi A, Barghash M, Lala A, Mitter SS, Parikh A, Oliveros E, et al. Challenges in Heart Transplantation during COVID-19: A Single Center Experience. *J Hear Lung Transplant [Internet].* 2020; Available from: <https://doi.org/10.1016/j.healun.2020.06.015>
41. Antony SJ, Singh J, de Jesus M, Lance J. Early use of tocilizumab in respiratory failure associated with acute COVID -19 pneumonia in recipients with solid organ transplantation. *IDCases [Internet].* 2020;21:e00888. Available from: <https://doi.org/10.1016/j.idcr.2020.e00888>
42. Kates OS, Fisher CE, Stankiewicz-Karita HC, Shepherd AK, Church EC, Kapnadak SG, et al. Earliest cases of coronavirus disease 2019 (COVID-19) identified in solid organ transplant recipients in the United States. *Am J Transplant.* 2020;20(7):1885-90.
43. Fung M, Chiu CY, DeVoe C, Doernberg SB, Schwartz BS, Langelier C, et al. Clinical Outcomes and Serologic Response in Solid Organ Transplant Recipients with COVID-19: A Case Series from the United States. *Am J Transplant.* 2020;0-2.
44. Fernández-Ruiz M, Andrés A, Loinaz C, Delgado JF, López-Medrano F, San Juan R, et al. COVID-19 in solid organ transplant recipients: A single-center case series from Spain. *Am J Transplant.* 2020;20(7):1849-58.
45. Ghaffari Rahbar M, Nafar M, Khoshdel A, Dalili N, Abrishami A, Firouzan A, et al. Low Rate of COVID-19 pneumonia in Kidney Transplant Recipients-A Battle Between Infection and Immune Response? *Transpl Infect Dis.* :e13406.
46. Zhu L, Xu X, Ma K, Yang J, Guan H, Chen S, et al. Successful recovery of COVID-19 pneumonia in a renal transplant recipient with long-term immunosuppression. *Am J Transplant.* 2020;20(7):1859-63.
47. Abrishami A, Samavat S, Behnam B, Arab-Ahmadi M, Nafar M, Sanei Taheri M. Clinical Course, Imaging Features, and Outcomes of COVID-19 in Kidney Transplant Recipients. *Eur Urol [Internet].* 2020;78(2):281-6. Available from: <https://doi.org/10.1016/j.eururo.2020.04.064>

48. Nair V, Jandovitz N, Hirsch JS, Nair G, Abate M, Bhaskaran M, et al. COVID-19 in kidney transplant recipients. *Am J Transplant.* 2020;20(7):1819–25.
49. Huang JF, Zheng KI, George J, Gao HN, Wei RN, Yan HD, et al. Fatal outcome in a liver transplant recipient with COVID-19. *Am J Transplant.* 2020;20(7):1907–10.
50. Laracy JC, Verna EC, Pereira MR. Antivirals for COVID-19 in Solid Organ Transplant Recipients. *Curr Transplant Reports.* 2020;7(4):355–65.
51. Pereira MR, Aversa MM, Farr MA, Miko BA, Aaron JG, Mohan S, et al. Tocilizumab for severe COVID-19 in solid organ transplant recipients: a matched cohort study. *Am J Transplant.* 2020;20(11):3198–205.
52. Behrens G, Dejam A, Schmidt H, Balks HJ, Brabant G, Körner T, et al. Impaired glucose tolerance, beta cell function and lipid metabolism in HIV patients under treatment with protease inhibitors. *Aids.* 1999;13(10):1–8.
53. Marano G, Vaglio S, Pupella S, Facco G, Catalano L, Liembruno GM, et al. Convalescent plasma: New evidence for an old therapeutic tool? *Blood Transfus.* 2016;14(2):152–7.
54. Rojas M, Rodríguez Y, Monsalve DM, Acosta-ampudia Y, Camacho B, Esteban J, et al. Since January 2020 Elsevier has created a COVID-19 resource centre with free information in English and Mandarin on the novel coronavirus COVID-19. The COVID-19 resource centre is hosted on Elsevier Connect, the company's public news and information. 2020;(January).
55. Eckhardt CM, Cummings MJ, Rajagopalan KN, Borden S, Bitan ZC, Wolf A, et al. Correction to: Evaluating the efficacy and safety of human anti-SARS-CoV-2 convalescent plasma in severely ill adults with COVID-19: A structured summary of a study protocol for a randomized controlled trial (*Trials*, (2020), 21, 1, (499), 10.1186/s13063-020-04422-y). *Trials.* 2020;21(1):20–2.
56. Duan K, Liu B, Li C, Zhang H, Yu T, Qu J, et al. Effectiveness of convalescent plasma therapy in severe COVID-19 patients. *Proc Natl Acad Sci U S A.* 2020;117(17):9490–6.
57. Zhang J, Yang Y, Yang N, Ma Y, Zhou Q, et al. Effectiveness of intravenous immunoglobulin for children with severe COVID-19: a rapid review. *Ann Transl Med.* 2020;8(10):625–625.
58. Mohtadi N, Ghaysouri A, Shirazi S, Sara Ansari, Shafiee E, Bastani E, et al. Recovery of severely ill COVID-19 patients by intravenous immunoglobulin (IVIG) treatment: A case series. *Virology.* 2020;548(January):1–5.
59. Cao W, Liu X, Bai T, Fan H, Hong K, Song H, et al. High-dose intravenous immunoglobulin as a therapeutic option for deteriorating patients with coronavirus disease 2019. *Open Forum Infect Dis.* 2020;7(3):1–6.