

# Transnasal Endoscopic Surgical Repair of Cerebrospinal Fluid(CSF) Rhinorrhea by Inferior Turbinate Grafts

Muhammad Saleem<sup>1</sup>, Naeem ur Rehman<sup>2</sup>, Raina Khan<sup>3</sup>, Ashar Alamgir<sup>4</sup>, Sarwat Bibi<sup>5</sup>, Humaira Ahmad<sup>6</sup>

<sup>1</sup> Associate Professor, Department of Otorhinolaryngology, AFMDC, Faisalabad.

<sup>2</sup> Associate Professor, Department of Neurosurgery, AFMDC, Faisalabad.

<sup>3</sup> House Officer, Department of Medicine (M4), District Head Quarter Hospital, Faisalabad.

<sup>4</sup> Assistant Professor, Department of ENT, Rawalpindi Medical University, Rawalpindi.

<sup>5</sup> Associate Professor, Department of Surgery, AFMDC, Faisalabad.

<sup>6</sup> Associate Professor, Department of Anesthesia & Intensive Care, AFMDC, Faisalabad.

## Author's Contribution

<sup>1,2</sup> Conception of study

<sup>1</sup> Experimentation/Study conduction

<sup>3</sup> Analysis/Interpretation/Discussion

<sup>1,3</sup> Manuscript Writing

<sup>4</sup> Critical Review

<sup>5,6</sup> Facilitation and Material analysis

## Corresponding Author

Dr. Muhammad Saleem,

Associate Professor,

Department of Otorhinolaryngology,

Aziz Fatimah Medical & Dental College,

Faisalabad

Email: drsaleementspt@gmail.com

## Article Processing

Received: 04/06/2021

Accepted: 13/09/2021

**Cite this Article:** Saleem, M., Rehman, N., Khan, R., Alamgir, A., Bibi, S., Ahmad, H. Transnasal Endoscopic Surgical Repair of Cerebrospinal Fluid(CSF) Rhinorrhea by Inferior Turbinate Grafts. *Journal of Rawalpindi Medical College*. 30 Sep. 2021; 25(3): 409-413.  
DOI: <https://doi.org/10.37939/jrmmc.v25i3.1696>

**Conflict of Interest:** Nil  
**Funding Source:** Nil

**Access Online:**



## Abstract

**Objective:** The study aims to evaluate the outcomes of transnasal endoscopic surgical repair of CSF rhinorrhoea.

**Materials and Methods:** After approval from the institutional ethical committee (DME-396-18) and patient consent, a descriptive study of 27 patients with cerebrospinal fluid rhinorrhea was conducted at Aziz Fatimah Trust Hospital Faisalabad from August 21, 2018, to February 7, 2021. Transnasal endoscopic surgical repair of Cerebrospinal fluid leak was performed by using multilayer technique using a graft from the inferior turbinate. The data collected were analyzed using SPSS 20.

**Results:** The most common site of the CSF leak was the left side of the cribriform plate (n=19,70%). The most common etiology was spontaneous (n=16,59%). At the same time, traumatic CSF leak (n=16,59%) was the second common etiological factor. The surgical procedure used in the study reported a 93%(n=25) success rate. The success rate was 97.5% on revision surgeries.

**Conclusion:** Transnasal endoscopic surgical repair of CSF leak is one of the most effective and safe surgical interventions. Multilayer technique is not only safe but also has lesser complications. Moreover, this minimizes the risk for the development of secondary wounds as compared to other surgical processes.

**Keywords:** cerebrospinal fluid, CSF, rhinorrhoea, transnasal endoscopic repair, inferior turbinate.

## Introduction

Cerebrospinal fluid (CSF) rhinorrhea is defined as leakage of CSF from the nasal cavity. CSF Rhinorrhea is caused by abnormal communication between the subarachnoid space and the upper respiratory tract due to numerous etiological factors. Depending on the etiology, CSF leak is classified into two main categories, traumatic and non-traumatic. Traumatic etiology comprises of accidental fracture of the skull base or as a consequence of surgical complication. In contrast, non-traumatic etiology comprises all spontaneous and with or without raised intracranial pressure cases.<sup>1</sup>

A patient with CSF leak classically presents with the flow of clear fluid on bending the head in the forward direction in the form of drops. The diagnosis of CSF leak depends on the brief history of the above-mentioned etiological factors. Biochemical analysis and radiological investigations are used as confirmatory tests to assess the location of the lesion, respectively.<sup>2</sup>

The first-line management is the conservative approach. The patient is advised to take bed rest, keep the head elevated, and be advised medications such as diuretics and restricted fluid intake.<sup>3</sup> CSF leaks due to accidental (traumatic) etiology mostly heal within few days. However, failure to respond to conservative treatment carries a high risk of intracranial infections. Patients who do not respond to conservative treatment need surgical management.<sup>4</sup> The radiological investigations such as Computerized tomography scans (CT-Scan) and Magnetic resonance imaging (MRI) are the investigations of choice.<sup>5</sup>

The treatment of CSF rhinorrhea is complex and debatable. The conservative approach is advised to treat the cause of CSF leak, which comprises bed rest, diuretics, and other medications that treat the cause.<sup>3,6</sup> If the patient shows no response to conventional or conservative treatment, surgical treatment is recommended. The surgical interventions are classified into two types, the intracranial approach (leak repaired via Craniotomy) and the extracranial approach (Transnasal endoscopic repair). The extracranial approach, such as the transnasal endoscopic surgical repair, has proved to be surgical interventions with minimal complications and a high success rate.<sup>1,7</sup> Surgical repair by Craniotomy was performed in the past, with a 60-80% success rate. Whereas open surgical repair requires a wide coronal incision with a high risk of permanent anosmia as a major complication.<sup>8</sup>

Recent advances in endoscopic transnasal approaches have changed the course of surgery, minimizing the risk of complications to a greater extent. It gives excellent exposure, better and greater magnification of the defects. These added advantages have completely replaced conventional open surgery with endoscopic repair as the first choice surgery over time. Endoscopic repair has numerous advantages, such as precise identification and access to the defect site and error-free placement of the graft. Trans-nasal endoscopic repair minimizes the risk of permanent anosmia.<sup>6,7</sup>

The current study provides a critical insight into transnasal endoscopic CSF rhinorrhea repair using grafts from the inferior turbinate.

## Materials and Methods

A cross-sectional, descriptive study was conducted on patients with a history of CSF rhinorrhea with different etiological factors at Aziz Fatimah Trust Hospital Faisalabad. The sampling technique was non-probability purposive, including all cases of CSF rhinorrhea presented in a defined period of three years. All other cases of nasal surgery were excluded from the study. After taking the ethical issue under DME/395-18 from the institutional ethical committee of Aziz Fatimah Medical and Dental College, Faisalabad. The patients were admitted and managed at the Otorhinolaryngology Department from August 21, 2018, to February 7, 2021. The data collected were analyzed using SPSS 20.

All patients who presented with a complaint of Cerebrospinal fluid leak were subjected to a brief history of onset, duration, etiological factors, aggravating and relieving factors, and associated comorbidities (i.e., hypertension, diabetes, meningitis). Reservoir sign (gushes of CSF fluid leak) was found on clinical examination. Biochemical test reports such as quantitative glucose measurements and HRCT (High resolution computed tomography) were performed to confirm the presence of CSF in the nasal discharge. The lesion site was identified using the high-resolution computed tomography of the skull and paranasal sinuses. (Figure 1)

The patients were admitted one day before the surgery for preoperative evaluation. The baseline investigations, including bleeding/clotting profile, complete blood count, Bleeding profile, hepatitis B and C profiles, were performed before the surgical procedure. Upon reporting of the standard values, the patients were subjected to surgery. Tablet Bromazepam and Inderal 40mg were prescribed to the

patients one night before the surgery to relieve fear and anxiety.

The surgical procedure was performed under general anesthesia with 4% Xylocaine and adrenaline subjected topically as a nasal pack, 10 minutes before the surgery for adequate vasoconstriction. Four injections of 2% Xylocaine with adrenaline were injected at the upper end of the middle turbinate near its attachment to the skull base, the middle part of the middle turbinate, osteo-meatal complex, and inferior turbinate. The anterior strip of the middle turbinate was dissected using bipolar diathermy and preserved in saline. Afterward, Uncinectomy was performed to expose the ethmoidal area in the Osteo-meatal complex. The mucosal tags were gently removed with bipolar diathermy until the leak was traced guided by the magnifying films obtained by High resolution computed tomography (HRCT). After successfully tracing the leak site, bipolar diathermy secured the bleeding, and the edge of the leak was widely made raw. The graft taken from the inferior turbinate was placed over the defect as a first layer, followed by the crush products of the middle turbinate placed gently as the second layer. (Figure 2) Fibrin glue and Surgicell were placed as third and fourth layers, respectively. In the end, Nasal packing with Bismuth Iodoform Paraffin Paste (BIPP) was kept for ten days alongside broad-spectrum antibiotics. The patients were prescribed Ceftriaxone (IV) B.D during their postoperative hospital stay for three days, followed by an oral antibiotic course of Macrolides, clarithromycin 500mg twice a day, and moxifloxacin 400mg once a day.

Post-operatively, patients were advised to complete bed rest and advised to keep the head slightly elevated in a propped-up position. Stool softeners and diuretics were prescribed for 5-7 days. The patients were kept under follow-up for the next two months to assess the minor and major complications.



Figure 1: CSF leak on the CT scan Film (Arrow indicates the CSF leak)

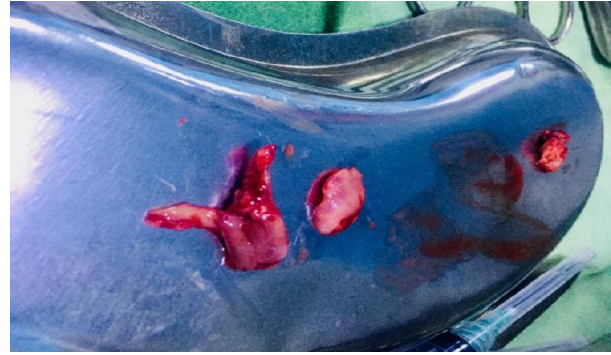

Figure 2: Graft taken from the inferior turbinate

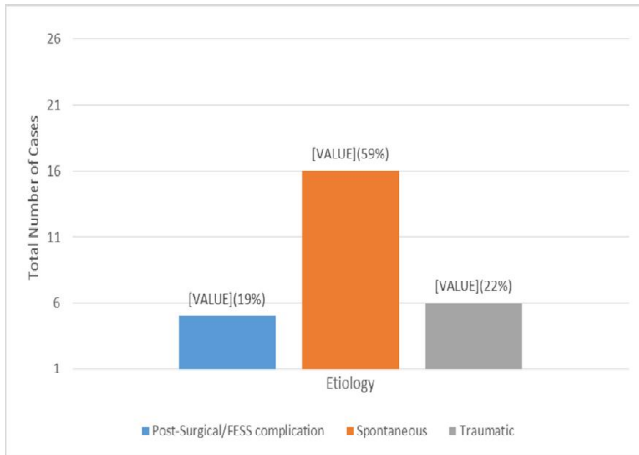
## Results

Our study comprised 27 patients who were confirmed cases of CSF rhinorrhea, of which 19 (70%) were females, and 8 (30%) were males. The age of the patients ranged from 19 years to 65 years with a mean age of  $38 \pm 12.18$ . The demographic profile of the patients has been listed in Table 1.

Table 1: Demographic Profile of the study (n=27)

Demographics	n (%)
<b>Age (years)</b>	
19-26	8 (30%)
27-34	4 (14%)
35-42	1 (4%)
43-50	12 (44%)
51-58	1 (4%)
59-66	1 (4%)
<b>Gender</b>	
Male	8 (30%)
Female	19 (70%)
<b>Socioeconomic Background</b>	
Rural	14 (52%)
Urban	13 (48%)

Etiological causes for CSF rhinorrhea are listed in Figure 1. Out of 27 cases, 6 (22%) cases of traumatic, 5 (19%) of Post-surgical/ functional endoscopic sinus surgery (FESS), and 16 (59%) of spontaneous etiology.



**Graph 1: Etiology of CSF Rhinorrhea**

The most affected side was the left in 23 (85%) than the right side in 4 (15%) patients under study. The site of leakage in our study was the cribriform plate (n= 19, 70%) sphenoidal sinus (n= 4, 15%), frontal sinus (n= 1, 4%) and anterior ethmoid (n= 3, 11%) illustrated in Table 2.

**Table 2: Site of leakage of CSF rhinorrhea (n=27)**

Site of Leakage	n (%)
Cribriform Plate	19 (70%)
Sphenoid Sinus	4 (15%)
Frontal sinus	1 (4%)
Anterior Ethmoid	3 (11%)
<b>Total</b>	<b>27 (100%)</b>

Multilayer surgical technique was used to treat all cases of CSF rhinorrhea. The patients were kept under follow-up for 2-3 months. Only Three cases treated recorded minor complications of nasal obstruction.

**Table 3: Success rate of the procedure (n=27)**

Success rate	N (%)
<b>Success</b>	25 (93%)
<b>Recurrence</b>	2 (7%)

The success rate of our surgical procedure was recorded at 25 (93%), with only 2 (7%) cases reported recurrence, which was corrected with revision surgery using a multilayer technique and fibrin adhesive glue. The revision success rate was 97%.

## Discussion

An untreated case of CSF rhinorrhea is a dangerous condition leading to chronic, life-threatening

conditions such as meningitis and brain abscess. CSF leak results from the tear or fracture in the skull base, which causes the cerebrospinal fluid to leak through the nose.<sup>9</sup>

The current study showed female predominance. The majority of cases reported were of spontaneous etiology. Similarly, another study reported the high prevalence of spontaneous cerebrospinal fluid leak among females associated with obesity.<sup>10</sup> Similarly, Bhatti et al. also reported female predominance in his study at Ayyub medical college, Abbottabad, and Pakistan.<sup>11</sup> The second most common cause of CSF leak was trauma, with male predominance in these cases. The high prevalence of this etiology among men is because men occupy riskier jobs and are more susceptible to trauma than females. Our study results match with the study results of Mohamad H. Mansour, in which there was a high incidence of CSF leak in males.<sup>1</sup>

In this study, the most common site of the leak was the cribriform plate (n= 19, 70%). According to the literature, the cribriform plate is considered the thinnest and weakest area of the anterior skull base. The results of our study are similar to another study which reports 184/227 (81.25%) cases with CSF leak from the cribriform plate.<sup>1,11</sup>

All the cases were treated using a multilayer technique using the graft from the inferior turbinate. Various literature evidence advocates a success rate of more than 90%. Sharma et al. reported 90%, Banks et al., and Rohit et al. 91%, while Lee et al. and Ishfaq et al. reported a 92 and 90% success rate, respectively.<sup>12,13,14,15</sup> The result of another study is similar to the repair outcomes by Singh and colleagues, with a success rate of 91% in attempts at using the septal cartilage with soft tissue graft & gel foam.<sup>16</sup> In our study, the success rate was 93%, which supports using the endoscopic repair of CSF leak. Numerous literature evidence suggests endoscopic surgery for CSF leak as the first choice surgical treatment.<sup>12</sup>

According to the literature, recurrence of CSF leak in sphenoid sinus may be seen due to complex approach during the endoscopic repair.<sup>13</sup> The present study reports a unique and less invasive procedure using the transnasal endoscopic approach to treat patients with CSF rhinorrhea. This modern technique is widely accepted and recommended.

## Conclusion

Transnasal endoscopic repair of CSF rhinorrhea is currently the widely accepted procedure using the multilayer technique. The graft taken from inferior turbinate reduces the risk of secondary wound and increases the surgeon's convenience during the surgery.

## References

1. Mansour M, Abdelgelil A, Ibraheem M, Dawood Y. Surgical outcome of endoscopic repair of cerebrospinal fluid rhinorrhea. *Al-Azhar Assiut Med J.* 2018; 16(3):247–54. Available from: <http://www.azmjg.net/article.asp?issn=1687-1693>.
2. Locatelli D, Rampa F, Acchiardi I, Bignami M, De Bernardi F, Castelnovo P. Endoscopic endonasal approaches for repair of cerebrospinal fluid leaks: nine-year experience. *Neurosurgery.* 2006; 58(4):246–57.
3. Sharma DP, Singh D, Sinha S, Srivastva AK, Singh H, Jagetia A, et al. CSF rhinorrhea: An overview of endoscopic repair. *Indian J Neurotrauma.* 2010; 7(2):157–62. Available from: <https://www.sciencedirect.com/science/article/pii/S0973050810800322>.
4. Zweig JL, Carrau RL, Celin SE, Schaitkin BM, Pollice PA, Snyderman CH, et al. Endoscopic repair of cerebrospinal fluid leaks to the sinonasal tract: predictors of success. *Otolaryngol Neck Surg Off J Am Acad Otolaryngol Neck Surg.* 2000; 123(3):195–201.
5. Yadav YR, Parihar V, Janakiram N, Pande S, Bajaj J, Namdev H. Endoscopic management of cerebrospinal fluid rhinorrhea. *Asian J Neurosurg.* 2016; 11(3):183–93. Available from: <https://pubmed.ncbi.nlm.nih.gov/27366243>.
6. Anand VK, Murali RK, Glasgold MJ. Surgical decisions in the management of cerebrospinal fluid rhinorrhoea. *Rhinology.* 1995; 33(4):212–18.
7. Kljajić V, Vuleković P, Vlaški L, Savović S, Dragičević D, Papić V. Endoscopic repair of cerebrospinal fluid rhinorrhea. *Braz J Otorhinolaryngol.* 2017; 83(4):388–93.
8. Lindstrom DR, Toohill RJ, Loehrl TA, Smith TL. Management of cerebrospinal fluid rhinorrhea: the Medical College of Wisconsin experience. *Laryngoscope.* 2004; 114(6):969–74.
9. Mirza S, Thaper A, McClelland L, Jones NS. Sinonasal cerebrospinal fluid leaks: management of 97 patients over 10 years. *Laryngoscope.* 2005; 115(10):1774–77.
10. Badia L, Loughran S, Lund V. Primary spontaneous cerebrospinal fluid rhinorrhea and obesity. *Am J Rhinol.* 2001; 15(2):117–20.
11. Bhaffi SN, Khan SA, Shah R, Aurangzeb A, Ahmed E, Rizvi F, et al. Trans nasal endoscopic repair of cerebrospinal fluid rhinorrhea. *J Ayyub Med College Abbott.* 2011; 23 (2): 15-7.
12. Sharma DP, Singh D, Sinha S, Srivastva AK, Singh H, Jagetia A. CSF rhinorrhea: An overview of endoscopic repair. *J Ind Neurotr.* 2010; 2 (7): 157-62.
13. Banks CA, Palmer JN, Chiu AG, O'Malley BW Jr, Woodworth BA, Kennedy DW, et al. Endoscopic closure of CSF rhinorrhea: 193 cases over 21 years. *Otolaryngol Head Neck Surg.* 2009; 140: 826–33
14. Rohit S, Produl H, Nayak DR, Balakrishanan R, Hazarika M, Ansulsingh K, et al. Endoscopic repair of cerebrospinal fluid Rhinorrhea-manipal Experience. *Ind J Otolaryngol Head Neck Surg.* 2009; 61 (1): 14-8.
15. Ishfaq, M., Abbas, T., Akmal, M., Choudhry, N., Hassan, A. U., Afzal, O., Siddiqui, I., & Mahmood, K. (2019). Outcome of Endoscopic Repair of CSF Rhinorrhea with Endonasal Endoscopic Approach in terms of Success of Repair. *Pakistan Journal Of Neurological Surgery,* 23(4), 257–263. <https://doi.org/10.36552/pjns.v23i4.378>
16. Chowdhury F, Haque M, Islam M, Kawsar K, Sarkar M. Endoscopic transnasal repair of CSF rhinorrhea: Techniques and outcome. *Bangladesh J Otorhinolaryngol.* 1970; 17(1). Available from: <https://www.banglajol.info/index.php/BJO/article/view/7618>.
17. Marton E, Billeci D, Schiesari E, Longatti P. Transnasal endoscopic repair of cerebrospinal fluid fistulas and encephaloceles: surgical indications and complications. *Minimally Invasive Neurosurg.* 2005; 48(3):175–80.
18. Psaltis AJ, Schlosser RJ, Banks CA, Yawn J, Soler ZM. A systematic review of the endoscopic repair of cerebrospinal fluid leaks. *Otolaryngol Neck Surg.* 2012; 147(2):196–203.
19. Kong, YG., Deng, YQ. & Wang, Y. Transnasal Endoscopic Repair of Cerebrospinal Fluid Rhinorrhea: An Analysis of 22 Cases. *Indian J Otolaryngol Head Neck Surg.* 2013; 65(2):409–14. <https://doi.org/10.1007/s12070-013-0628-8>.
20. Sandhu KS, Chopra L, Singh J, Arya S. Very late presentation of CSF rhinorrhoea after 45 years of head trauma: a case report. *Iran J Otorhinolaryngol.* 2021; 33(115):103-06.
21. Yoneoka Y, Aizawa N, Nonomura Y, Ogi M, Seki Y, Akiyama K. Traumatic nonmissile penetrating transnasal anterior skull base fracture and brain injury with cerebrospinal fluid leak: Intraoperative leak detection and an effective reconstruction procedure for a localized skull base defect especially after corona virus disease 2019 outbreak. 2020; 140:16-72.