

Retinoblastoma - Clinical Spectrum and Treatment Outcome in Children

Alia Ahmad¹, Fauzia Shafi Khan², Wasila Shamim¹, Asif Hanif³, Carlos Rodriguez-Galindo⁴

1. Department of Paediatric Haematology/Oncology, Children's Hospital, Lahore; 2 Department of Paediatric Haematology & Transfusion Medicine, Children's Hospital, Lahore; 3. Gulab Devi Hospital, Lahore; 4. Department of Global Pediatric Medicine St. Jude Children's Research Hospital, Memphis TN, USA

Abstract

Background: To analyze outcome of retinoblastoma (RB) in resource limited settings

Methods: In this descriptive study, patients of retinoblastoma were treated according to UKCCSG RB 2005 11 protocol with main chemotherapy including Vincristine, Etoposide, Carboplatin and intrathecal Cytarabine called JOE protocol. These protocols were given 3 weeks apart in the chemotherapy bay on outpatient basis. Total 6 courses were given to these patients. The patients presenting with huge tumour with proptosis were offered two courses of chemotherapy (Neoadjuvant) before Enucleation (Removal of orbit and optic nerve) done as upfront Enucleation not possible without mutilating surgery-Exenteration. In our study Group A included patients who refused Enucleation and opted out of recommended treatment plan and Group B patients had Enucleations done and followed treatment plans

Results: Total 68 patients with age ranging from < 1 to 7 years (95% < 5 yrs) were included. Thirty seven percent presented with bilateral retinoblastoma, fifty six percent with optic nerve involvement and 18% with brain metastasis. 30/68(44%) defaulted treatment, and 33/68 (49%) refused enucleation at diagnosis. Only 3/68(5%) had bilateral enucleation and 50/68(73%) unilateral enucleation with laser therapy in 7/68(10%). Total 52% completed treatment, 26% left against medical advice and 9% expired due to metastatic and progressive disease and sepsis. 9/68 (13%) patients relapsed. Neoadjuvant chemotherapy was given in 59% with 61% of total abandonment and 50% of deaths in this group. The number of bilateral RB was increased to 37% as compared to 18%. Abandonment increased from 13% to 26%.

Conclusion: Mortality of 9% can be reduced by early diagnosis and early treatment. Management of RB needs efficient multidisciplinary team and long

term sustainable programs to improve survival. The Neoadjuvant group needs extensive follow up and counselling to decrease abandonment.

Key Words: Retinoblastoma, neoadjuvant chemotherapy, UKCCSG RB 2005 11 protocol, Enucleation

Introduction

While Retinoblastoma is highly curable in developed countries, the outcome is still dismal in Pakistan. Retinoblastoma is the most common primary intraocular malignancy in paediatric population. When Retinoblastoma is diagnosed in early intraocular stages the probability of disease free survival in good centers have been 80-90% with Enucleation of the affected eye, a simple surgical procedure usually curative in intraocular retinoblastoma.¹ RB is one of the more common malignancies in paediatric oncology in developing countries. The annual incidence of retinoblastoma in USA is 3.8 cases per million and higher in Africa up to 20 cases per million children under 5 with survival rates upto 30% and up to seven times that of Western Europe (4.1 per million) in Brazil and Mexico evidenced by population based studies and cancer registries data.^{2,3}

In developed countries, sophisticated conservative strategies are used to preserve eyes with useful vision without changing the survival. Although these outcomes are very encouraging but the majority of the 8,000 children diagnosed with RB worldwide have not benefited from these trends. In developing countries the diagnosis is made quite late with extraocular metastasis therefore ocular and patient survival rates are much lower than in developed countries as it is difficult to treat even with most sophisticated and intense regimens.⁴ These cases depict longer lag times from the onset of symptoms to the final diagnosis made.⁵ Another critical factor greatly influencing the outcome is therapy refusal by parents against

recommended medical advice, however late diagnosis is given more attention than families opting out of treatment in literature.⁶ Therefore survival of these children in developing countries is affected by socioeconomic and cultural factors causing delays leading to extra-ocular dissemination than by the unavailability of advanced treatments as described for other childhood malignancies as ALL or other solid tumors.⁷

In developing countries, multiple factors including late referrals due to lack of parental education and awareness among health professionals for early signs resulting in delayed diagnosis with extra-ocular presentation in 50 % of cases along with refusal of Enucleation and incomplete treatment. To improve survival and vision it is imperative to improve the referral systems with increased awareness of doctors and parents by community outreach program.⁸

Patients and Methods

In this descriptive study , performed in department of Paediatric Haematology/Oncology of the Children’s Hospital & the Institute of Child Health Lahore from June 2013 to December 2015, patients of retinoblastoma were included. Patients were treated according to UKCCSG RB 2005 11 protocol with main chemotherapy including Vincristine, Etoposide, carboplatin and intrathecal Cytarabine called JOE protocol. Doses calculated according to body surface area. These protocols were given 3 weeks apart in the chemotherapy bay on outpatient basis. Total 6 courses were given to these patients. The patients presenting with huge tumor with proptosis were offered two courses of chemotherapy (Neoadjuvant) before Enucleation (Removal of orbit and optic nerve) done as upfront Enucleation not possible without mutilating surgery-Exenteration. In our study Group A includes patients who refused Enucleation and opted out of recommended treatment plan and Group B patients had Enucleations done and followed treatment plans.

Results

Total 68 patients with age ranging from< 1 to 7 years (95% <5 yrs) were included (Table 1). M: F Ratio was 1:1. These patients mainly presented with leukocoria of affected eye, squint and proptosis and huge disfiguring tumors or fungating masses along with loss of vision of the affected eye. (Figure 1& 2). Thirty seven percent (25/68) presented with bilateral Retinoblastoma and 38/68 (56%) with optic nerve involvement (Figure B & D) and brain metastasis 12/68(18%). (Figure 3-6).30/68(44%) defaulter

treatment (Table 2), and 33/68 (49%) refused Enucleation at diagnosis (Table 3). Only 3/68(5%) had bilateral Enucleation and 50/68(73%) unilateral Enucleation with laser therapy in 7/68(10%).Total 35/68 (52%) have completed treatment, 18/68 (26%) left against medical advice (LAMA) and 6/68 (9%) expired due to metastatic and progressive disease and sepsis. 9/68 (13%) patients relapsed (Table 4). Neoadjuvant chemotherapy was given in 40/68 (59%) with 61% of total abandonment and 50% of deaths in this group. When compared with the previous study presented in SIOP 2014 mortality decreased from 18 to 9% and defaulter trend decreased from 66% to 44% (30/68) and Neoadjuvant chemotherapy used in 59% cases as compared to 54%.The number of bilateral RB was increased to 25/68(37%) as compared to 10/56(18%).Abandonment increased from 13% to 26%.

Table1: Age distribution

Age (years)	< 1r	1-5	>5
Number	20	44	4
%	30%	65%	5%

<5 Years=95%

Table2: Pattern of treatment course

Parameters	Group A (Yes)	Group B (No)	p-Value
Defaulter Treatment	30(44%)	38(56%)	0.000

p-value<0.05 is statistically significant

Table 3: Refusal of enucleation

Parameter	Group A (Yes)	Group B (No)	p-value
Refused Enucleation	33 (49%)	35 (51%)	0.002

p-value<0.05 is statistically significant

Table4: Outcome of Retinoblastoma

	LAMA	Expired	Treatment Completed	Relapsed
Number	18	6	38	5
%	26	9	52	7

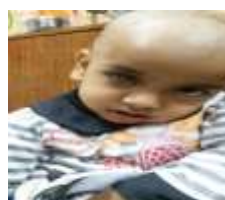

Figure 1:Extraocular Presentation

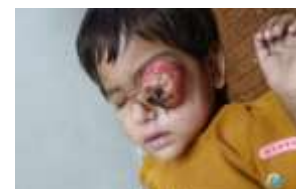

Figure 2: Leukocoria Right Eye

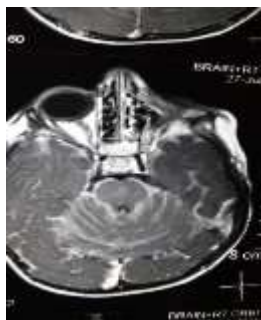

Figure 3. T1W MRI brain with contrast, axial section Through orbits demonstrate meningeal metastasis

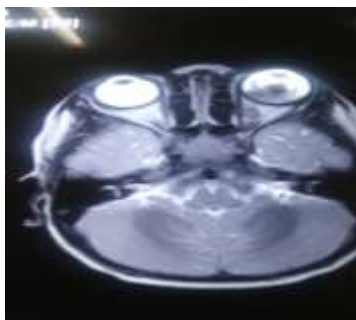


Figure 4: T2W MRI brain, hypointense mass in Left orbit with left optic nerve involvement section

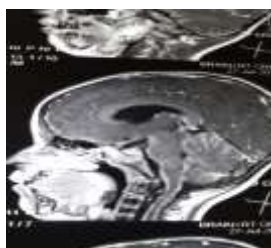

Figure 5: T1W MRI brain sagittal section demonstrates diffuse meningeal metastasis

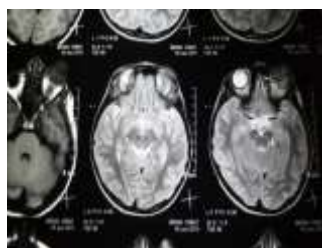


Figure 6: Multiechoic MRI demonstrates heterogenous signal in left orbit with left optic nerve involvement

Discussion

In present study only 29% cases presented before one year of age and more than two thirds duration of symptoms longer than three months before diagnosis (lag period) significant predictors for presence of pathological high risk factors (HRF) indication need of adjuvant chemotherapy and radiotherapy. The mean age of diagnosis in Western children is reported as 18 months and median age at diagnosis in Indian children was 24 months.⁹ Delayed diagnosis is one of the two most important causes of advanced disease at presentation in developing countries as well as diagnosis at later ages as compared to the developed countries.¹⁰ The importance of lag time between presentation of symptoms and diagnosis with outcome modification was firstly emphasized by Brazilian researchers.¹⁰ This can be encouraged in LIC (Low Income Countries) where majority of patients present with advanced disease and high eventual mortality as in MIC/ developed countries survival increases up to 80% so they are focusing more on eye and vision preservation by doing screening of familial

Retinoblastoma cases which is still as low as 23% in developing countries.^{11,12}

The second most important point in our study is behavior of families opting out of recommended treatment whether chemotherapy or Enucleation even if timely diagnosis is made in good centers.⁶ In our study 49% refused Enucleation at diagnosis and 44% defaulted chemotherapy with overall poor survival. 64% received chemotherapy at delayed schedules after Enucleations and 26% cases didn't receive any treatment. As these patients were not treated in time with surgery, chemotherapy and radiotherapy they relapsed (13%) as compared to 3% in MIC and died (9%) due to progressive disease.¹³ So in our study 52% cases able to complete therapy successfully and they are well but need further follow up and monitoring, the rest 48% eventually expired due to Retinoblastoma. Though estimated survival rate in LIC is 30% with 35% cases presenting in advanced stages and 40% refusing Enucleation and further management in Asia, Africa and Central America.¹⁴ In MIC (Middle Income Countries) Estimated survival is 60-75% cases with 10-15% cases presenting in advanced stages and only 30% estimated cases opting out of treatment while this trend is only 1% in HIC (High Income Countries with 95% estimated survival rate with 3% cases presenting in advanced stages at presentation.¹⁴

In present study optic nerve involvement was present in 56% lower than in African Countries 68% to 78% but higher than in France 45% (1977-1990) but much lesser currently (3%) with increased risk of orbital and metastatic disease.^{2,19} In India there was 17% retrolaminar optic nerve involvement and 9% extrascleral and optic nerve transection invasion classified as microscopic residual disease and in 326 eyes over a period of 5 years and with median age of presentation 2 years requiring postoperative adjuvant chemotherapy and radiotherapy.⁹

Neoadjuvant chemotherapy was given in 59% cases but data showed increased abandonment and deaths in this group though there are good results with up to 70% disease free survival with different chemotherapy regimens using etoposide, ifosfamide and anthracyclines and up to 56% survival with less intensive chemotherapy in LIC like Mali.^{15, 17} In advanced cases involving CNs and distant metastases routine chemotherapy and radiotherapy gives dismal results with eventual relapse and ultimately death in LIC and adequate palliation should be provided for these children but unfortunately is not adequately available in many centers.¹⁸

While Eye conserving treatment in developed countries is the standard of care, we are struggling hard to save these children as they present very late and then they don't adhere to the planned treatment. A more focus on how to improve acceptance of families for life saving procedure of enucleation and compliance of treatment and improved palliative and supportive care services as high intensity chemotherapy regimens are required to treat them and provision of adequate facilities for EBRT (external Beam Radiotherapy).^{14, 20} As disease free survival in LIC is <50% with >30% presenting with metastatic disease at diagnosis due to mainly sociocultural factors like treatment nonadherence and late diagnosis partly due to paucity of efficient multidisciplinary treatment centers it's the need of time to establish awareness campaigns for early referrals. Early diagnosis campaigns, programs to prevent treatment nonadherence and twinning programs with high-income countries to increase survival like St.Jude Children Research Hospital USA.¹⁴ The need of multidisciplinary treatment centers in developing countries cannot be overemphasized for better management with significant roles of highly trained histopathologists, critical for identifying high risk patients as if missed and not given adjuvant chemotherapy might eventually progress and die of metastatic retinoblastoma.¹⁴ Trained radiologist, radiation oncologist and paediatric oncologist with improved supportive care services while giving intensive chemotherapy regimens and palliative care services are essential.^{21,22}

Conclusion

Mortality of 9% can be reduced by early diagnosis and early treatment. The Neoadjuvant group needs extensive follow up and counseling to decrease abandonment.

References

1. MacCarthy A, Birch JM, Draper GJ. Retinoblastoma: Treatment and survival in Great Britain 1963 to 2002. *Br J Ophthalmol* 2009; 93:38-39
2. Bowman RJC, Mafwiri M, Luthert P. Outcome of Retinoblastoma in East Africa. *Pediatr Blood Cancer* 2008; 50:160-62
3. MacCarthy A, Draper GJ, Steliarova-Foucher E. Retinoblastoma Incidence and Survival in European Children(1978-1997). Report from the Automated Childhood Cancer Information System project, *Eur J Cancer* 2006; 42:2092-2102
4. Canturk S, Qaddoumi I, Khetan V. Survival of retinoblastoma in less developed countries. Impact of socioeconomic and health related indicators. *Br J Ophthalmol* 2010; 10:168062-65
5. Chantada G, Fandino A, Manzitti J. Late diagnosis of Retinoblastoma in a developing country. *Arch Dis Child* 1999; 80: 171-74
6. Sitorus RS, Moll AC, Suhardjono S. The effect of therapy refusal against medical advice in retinoblastoma patients in a setting where treatment delays are common. *Ophthalmic Genet* 2009; 30: 31-36
7. Howard SC, Ortiz R, Baez LF. Protocol-based treatment for children with cancer in low income countries in Latin America: A report on the recent meetings of the Monza International School of Pediatric Hematology/Oncology (MISPHO) –Part II. *Pediatr Blood Cancer* 2007; 48: 486-90
8. Mehta M, Sethi S, Pushker M. Retinoblastoma: Still a challenge in developing countries. *Acta Ophthalmologica* 2011; 10:3768-71
9. Kayshyap S, Meel R, Pushker N. Clinical Predictors of High Risk Pathology in Retinoblastoma. *Pediatr Blood cancer* 2012; 58: 356-61
10. Erwenne CM and Franco EL. Age and lateness of referral as determinants of extra-ocular retinoblastoma. *Ophthalmic Pediatr Genet* 1989; 10: 179-84
11. Wallach M, Balmer A, Munier F. Shorter time to diagnosis and improved stage at presentation in Swiss patients with retinoblastoma from 1963- 2004. *Pediatrics* 2006; 118: 1493-98
12. Chantada GL, Dunkel IJ, Qaddoumi. Familial retinoblastoma in developing countries. *Pediatr Blood cancer* 2009; 53: 338-42
13. Chantada GL, Fandino AC, Guitter MR, et al. Results of a prospective study for the treatment of unilateral retinoblastoma. *Pediatr Blood Cancer* 2010; 56: 60-66
14. Chantada GL, Qaddoumi I, Canturk S. Strategies to Manage Retinoblastoma in Developing Countries. *Pediatr Blood Cancer* 2011; 56: 341-48
15. Boubacar T, Fatou S, Fousseyni T. A 30-month prospective study on the treatment of retinoblastoma in the Gabriel Toure Teaching Hospital, Bamako, Mali. *Br J Ophthalmol* 2009; 94: 467-69
16. Bellaton E, Bertozzi AI, Behar C. Neoadjuvant chemotherapy for extensive unilateral retinoblastoma. *Br J Ophthalmol* 2003; 87: 327-29
17. Antoneli CB, Ribeiro KB, Rodriguez-Galindo C. The addition of ifosfamide/etoposide to cisplatin/teniposide improves the survival of children with retinoblastoma and orbital involvement. *J Pediatr Hematol Oncol* 2007; 29: 700-04
18. Leal-Leal CA, Rivera-Luna R, Flores-Rojo M. Survival in extra-orbital metastatic retinoblastoma: Treatment Results. *Clin Transl Oncol* 2006; 8: 39-44
19. Khelafauri F, Validire P, Auperin A. Histopathological risk factors in retinoblastoma. A retrospective study of 172 patients' treated in a single institution. *Cancer* 1996; 77: 1206-13
20. Shields CL, Ramasubramanian A, Thangappan A. Chemoreduction for group E retinoblastoma: Comparison of chemoreduction alone versus chemoreduction plus low-dose external radiotherapy in 76 eyes. *Ophthalmology* 2009; 116: 544-51.
21. Leander C, Fu LC, Pena A, et al. Impact of an education Program on late diagnosis of retinoblastoma in Honduras. *Pediatr Blood cancer* 2007; 49: 817-19
22. Rodriguez-Galindo C, Wilson MW, Chantada G. Retinoblastoma: one World, One Vision. *Pediatrics* 2008; 122:763-70.