

## Dysphagia among Middle-Aged Females

Nudrat Khalil<sup>1</sup>, Mirza Khizar Hameed<sup>2</sup>, Iftikhar Aslam<sup>3</sup>, Irshad Ali<sup>4</sup>, Amir Akbar<sup>5</sup>, Mahum Khizar<sup>6</sup>

<sup>1</sup> Senior Registrar, Foundation University Medical College, Islamabad.

<sup>2</sup> Professor and HOD ENT, Foundation University Medical College, Islamabad.

<sup>3</sup> Professor ENT, Foundation University Medical College, Islamabad.

<sup>4,5</sup> Assistant Professor ENT, Foundation University Medical College, Islamabad.

<sup>6</sup> House Officer, Foundation University Medical College, Islamabad.

### Author's Contribution

<sup>1,2,3</sup> Conception of study

<sup>1,3,4,5,6</sup> Experimentation/Study conduction

<sup>1,2,4,5</sup> Analysis/Interpretation/Discussion

<sup>2</sup> Manuscript Writing

<sup>2,3</sup> Critical Review

<sup>4,5,6</sup> Facilitation and Material analysis

### Corresponding Author

Dr. Mirza Khizar Hameed,

Professor and HOD ENT,

Foundation University Medical College,  
Islamabad

Email: mirzakhizar@yahoo.com

### Article Processing

Received: 14/12/2021

Accepted: 19/09/2022

**Cite this Article:** Khalil, N., Hameed, M.K., Aslam, I., Ali, I., Akbar, A., Khizar, M. Dysphagia among Middle-Aged Females. *Journal of Rawalpindi Medical College*. 30 Sep. 2022; 26(3): 431-434.

DOI: <https://doi.org/10.37939/jrmc.v26i3.1861>

**Conflict of Interest:** Nil

**Funding Source:** Nil

**Access Online:**



## Abstract

**Objective:** To find out the cause of dysphagia among the middle-aged females in our setup.

**Study Design:** Descriptive study.

**Study Setting & Duration:** Department of ENT at Fauji Foundation Hospital Rawalpindi from April 2019 to April 2021.

**Materials and Methods:** Approval of the study was obtained from the Hospital Ethical Committee and then Informed Consent was obtained from all the patients. A total of 42 female patients were selected by consecutive convenient sampling. Inclusion criteria were the complaint of progressive difficulty in swallowing and age group ranging from 30-65 years. Exclusion criteria included patients having a previous surgical intervention for dysphagia and patients not fit to undergo general anaesthesia. After detailed history and physical examination, Complete Blood Count and X-ray Barium Swallow were done in all these patients, followed by Rigid Endoscopy under General Anaesthesia. A tissue biopsy was done on all the patients from suspicious areas. The data were analyzed for frequencies by SPSS 24.

**Results:** 42 female patients were included in this study. The mean age of these patients was 46.30 years, ranging from 32 to 65 years. 40 (95%) of these patients showed Esophageal webs in the cricopharyngeal region, while 2 (5%) of them had irregular strictures in the post-cricoid region of the Hypopharynx. Iron deficiency anaemia was found in 32 (76.19%) patients. Histopathology report showed Squamous Cell Carcinoma in 2 patients with post cricoid strictures, while the rest 40 with webs showed chronic inflammation with fibrosis. Rigid esophagoscopy with web dilatation was a highly effective procedure for treatment in 40 (95%) patients. Repeated dilatations were needed in 14 (33%) of the patients. The 2 patients with malignancy underwent Chemo-radiotherapy.

**Conclusion:** Iron deficiency anemia has a strong association with dysphagia in middle-aged female patients and is a potential risk factor for malignant transformation. Timely diagnosis and prevention of anaemia may result not only in a decrease in Plummer-Vinson Syndrome but also in a decreased incidence of hypopharyngeal carcinoma in the vulnerable population.

**Keywords:** Dysphagia, Iron deficiency anemia, Post cricoid Carcinoma.

## Introduction

A trinity of dysphagia, esophageal web, and iron deficiency anemia is the hallmark of Plummer-Vinson Syndrome (PVS) among middle-aged females.<sup>1</sup> This syndrome was earliest described by Plummer in 1912 and later on it was attributed to Patterson-Brown in the U.K in 1920.<sup>2</sup> This syndrome is characterized by intermittent painless dysphagia, koilonychia, angular cheilitis, glossitis, and generalized weakness.<sup>3</sup> Waldenstorm called it "sideropenic dysphagia" and termed it a leading cause of Hypopharyngeal carcinoma.<sup>4</sup> Iron deficiency anemia has been blamed as a cause of Plummer-Vinson Syndrome. As iron deficiency is not very infrequent among females due to the presence of menstrual disorders, its frequency is quite high among middle-aged females.<sup>5</sup> Other nutritional factors considered important in causing PVS are thiamin, riboflavin, or pyridoxine.<sup>6</sup> Autoimmune diseases like Rheumatoid Arthritis, Sjogren's Syndrome, thyroiditis, etc, malnutrition, genetic predisposition, and Celiac disease are other factors that play role in its development.<sup>7</sup> Esophageal web present in PVS is formed as a shelf-like projection of normal esophageal tissue containing only mucosa and submucosa, although the exact mechanism of its formation is not known.<sup>8</sup> However, it has been observed that a rapid cellular exchange rate in the upper GI tract epithelium causes a deficiency of iron-dependent enzymes, thus low iron levels cause decreased activity of oxidative enzymes leading to changes in the mucosa.<sup>9</sup> These mucosal changes are usually distinct in the post-cricoid area as this region is subjected to maximal trauma during the swallowing of food. PVS is considered to be a premalignant condition as many of these cases progress to turn into carcinoma. This correlation between PVS and hypopharyngeal carcinoma was first established by Ahlbom in 1937.<sup>10</sup> The incidence of Squamous Cell Carcinoma (SCC) of post cricoid region in PVS is 4-16 %.<sup>11</sup> The occurrence of PVS is decreasing over the years but in developing countries like ours, it is still prevalent. Hence this study was done to assess the association of dysphagia with iron deficiency anemia in female patients.

## Materials and Methods

This descriptive study was conducted in the department of ENT at Fauji Foundation Hospital, Rawalpindi from April 2019 to April 2021, after approval from the Hospital Ethical Committee, and

informed consent for the study was also obtained from all the patients. The study was exclusively conducted on female patients. After informed consent, 42 patients who had presented with dysphagia and were diagnosed with esophageal web on barium swallow were selected for this study by consecutive convenient sampling. The patients with dysphagia due to foreign body, paralytic dysphagia, and recurrent carcinoma of the hypopharynx or dysphagia due to other causes were excluded from the study.

A detailed history was taken. A thorough ENT examination was performed. Complete Blood Count, along with other routine investigations, was performed in all the cases. Patients with hemoglobin less than 12g/dl, mean corpuscular volume (MCV) lower than 80 fl, mean corpuscular hemoglobin (MCH) lesser than 27 pg, mean corpuscular hemoglobin concentration (MCHC) lower than 31.5 g/dl and serum ferritin lower than 13 ug/L were accounted for iron deficiency anemia. X-ray Barium swallow was carried out in all these patients. Patients with anemia who were planned for web dilatation first underwent iron replacement therapy. A rigid esophagoscopy was carried out under general anesthesia. The esophageal web was dilated with Savary-Gillard bougies and a biopsy was taken from the webs/ constrictions in all the cases for histopathology. Patients were placed on iron replacement therapy for 3 months to build up iron stores. All these patients were followed up for 6 months.

## Results

A total of 42 female patients were included in this study. The mean age of these patients was 46.30 years, ranging from 32 to 65 years as shown in Figure 1. 40 (95%) of these patients showed Esophageal webs in the cricopharyngeal region, while 2 (5%) of them had irregular strictures in the post cricoid region of Hypopharynx. Iron deficiency anaemia was found in 32 (76.19%) patients as shown in Figure 2. Mean Hemoglobin was 9.8 gm/dl, MCV 69.07 fl, MCH 21.05 pg, MCHC 31g/dl, and mean serum ferritin levels were 14.82ug/L. Histopathology report showed Squamous Cell Carcinoma in 2 patients with post cricoid strictures, while the rest 40 with webs showed chronic inflammation with fibrosis. Rigid esophagoscopy with web dilatation was a highly effective procedure for treatment in 40 (95%) patients. Repeated dilatations were needed in 14 (33%) of the patients. The 2 patients with malignancy underwent Oncological treatment. Patients with anemia were

placed on iron replacement therapy for 3 months. None of the patients developed any post-dilation complications. These patients were followed up for 6 months. Patients with carcinoma hypopharynx were managed on oncological lines.

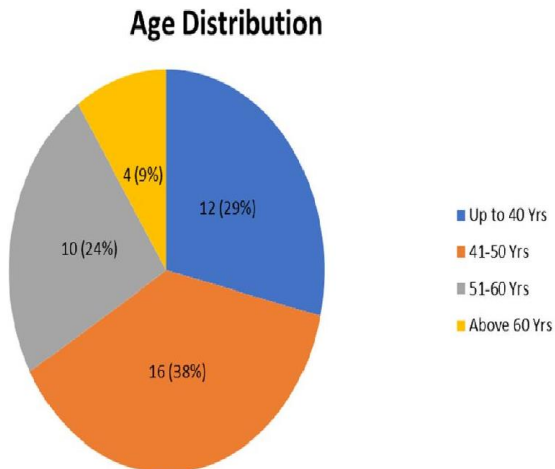


Figure 1: Age Distribution

### Association of Dysphagia with Anaemia

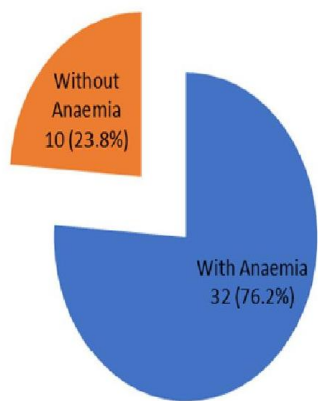


Figure 2: Association of Dysphagia with Anaemia

### Discussion

Incidence of PVS has been prevalent among Caucasians particularly in Scandinavia in the 60s but presently it may not be that common. But its peculiar geographical difference is still prevalent due to nutritional deficiencies, hematological disorders, and environmental factors.<sup>12</sup> In our study the mean age of these patients was 46.30 years (32-65 years) which is comparable to the average of 45 years in a study

conducted by Okamura et al.<sup>13</sup> Frequency of anemia associated with esophageal web formation was 76.19% in our study and similar results were inferred by Shamma'a in his study.<sup>14</sup> More or less similar results were shown in a study conducted by Bakari et al, where the association was 83.7%.<sup>15</sup> In another study by Daouda et al, iron deficiency anemia associated with dysphagia was 79%.<sup>16</sup> Similarly, Ben Gamra et al also indicated in their study that PVS was affiliated with dysphagia in 100% of the cases.<sup>17</sup> The treatment of PVS is based on iron supplementation and endoscopic dilatation.<sup>18</sup> This treatment was found effective in 40 (95%) patients in our study except for the 2 cases, which turned out to have post-cricoid carcinoma. Practically it was effective in all the patients, while Hefaiiedh et al showed that 80% of their patients had favorable outcomes with this treatment strategy.<sup>19</sup>

PVS may lead to malignant transformation (4-16%) and is considered a precancerous lesion.<sup>10</sup> In our study, malignancy within the post-cricoid region was diagnosed in 2 of the patients (5%). Hypopharyngeal tumors are generally squamous cell carcinoma (SCC) and this was coherent in our case where histopathology reports suggested SCC of post cricoid region.<sup>20</sup>

This study was carried out on a limited number of patients. Hence it is suggested that such studies should be carried out at the national level to reduce the incidence of PVS and Carcinoma hypopharynx among middle-aged females.

### Conclusion

Iron deficiency anemia has a strong association with dysphagia in middle-aged female patients and is a potential risk factor for malignant transformation. Timely diagnosis and prevention of anaemia may result not only in a decrease in PVS but also in a decreased incidence of hypopharyngeal carcinoma in the vulnerable population.

### References

- Goel A, Lakshmi CP, Bakshi SS, Soni N, Koshy S. Single-center prospective study of Plummer-Vinson syndrome. *Dis Esophagus*. 2016 Oct; 29(7):837-841.
- Tahara T, Shibata T, Okubo M, et al. A Case of Plummer-Vinson Syndrome showing rapid improvement of dysphagia and esophageal web after two weeks of iron therapy. *Case Rep Gastroenterol*. 2014; 8 (2): 211-215. DOI: 10.1159/000364820.
- Gedam DS, Mandliya J, Verma M. Plummer-Vinson Syndrome: A Case Report. *J. Nepal Paediatr. Soc*. 2011 Sep-Dec; 31(3):254-256.

4. Nasa M, Patil G, Sharma Z, Puri R. Plummer-Vinson syndrome with simultaneous mid-esophageal growth. *Assoc Physicians India*. 2017 Feb; 65(2):96-97.
5. Radochová V, Slezák R, Radocha J. Iron Deficiency as Cause of Dysphagia and Burning Mouth (Plummer-Vinson or Kelly-Patterson Syndrome): a Case Report. *Acta Medica (Hradec Kralove)*. 2020 Jan; 63(3):128-132.
6. Singh A, Yuwanati M, Umarji H, Gupta S. Plummer-Vinson Syndrome. *Journal of Oral Health Research*. 2013 Oct; 4(4):13-18
7. Novacek, G. Plummer-Vinson syndrome. *Orphanet J Rare Dis* 1, 36 (2006). DOI: <https://doi.org/10.1186/1750-1172-1-36>.
8. Patil M, Malipatel R, Devarbhavi H. Plummer – Vinson Syndrome: A Decade's Experience of 132 Cases from a Single Centre. *J Gastroenterol and Hepatol*. 2021 Jan; 36(1):181-185
9. Donohue-Cornejo A, Guzmán-Gastelum DA, Constandse-Cortéz D, Gaitán-Cepeda LA, Escalera CR. Squamous cell carcinoma in the tongue and Plummer-Vinson syndrome. A case report. *Revista Odontológica Mexicana*. Jun 2011; 15 (3): 189-192.
10. Watts JM. The importance of the Plummer-Vinson Syndrome in the aetiology of carcinoma of the upper gastro-intestinal tract. *Postgrad Med J*. 1961; 37: 523-533.
11. Goel A, Bakshi SS, Soni N, Chavvi N. Iron deficiency anemia and Plummer-Vinson syndrome: current insights. *J Blood Med*. 2017 Oct; 19(8):175-184.
12. Chaudhry MA, Alamgir A, Obaid A. Esophagoscopy in the early detection and treatment of Plummer Vinson Syndrome. *Journal of Rawalpindi Medical College (JRMCI)*; Jan 2008; 12(2): 37-40.
13. Okamura H, Tsutsumi S, Inaki S, Mori T. Esophageal web in Plummer-Vinson syndrome. *Laryngoscope*. 1988 Sep; 98(9):994-8.
14. Shamma'a MH, Benedict EB. Esophageal webs; A Report of 58 cases and an attempt at classification. *N Engl J Med*. 1958, 9 (8): 378-384. DOI: 10.1056/NEJM195808212590805.
15. Bakari G, Benelbarhdadi I, Bahije L, Essaid A. Endoscopic treatment of 135 cases of Plummer-Vinson web: a pilot experience. *Gastrointest Endosc*. 2014 Oct; 80(4):738-741
16. Daouda D, Mouhamadou M, Louise BM, Lamine DM (2013) Esophageal and Gastric Cancers in Sub-Saharan Africa, Epidemiological and Clinical Review. *J Gastroint Dig Syst* 56:007. DOI: 10.4172/2161-069X.S6-007
17. Ben Gamra O, Mbarek C, Mouna C, et al. Plummer-Vinson Syndrome, *Tunis Med* 2007; 85 (5): 402-404.
18. Petrea OC, Stanciu C, Muzica CM, et al. Idiopathic Cervical Esophageal Webs: A Case Report and Literature Review. *Int J Gen Med*. 2020 Nov; 2020(13): 1123–1127. DOI: 10.2147/IJGM.S278999.
19. Hefaiiedh R, Boutreaa Y, Ouakaa-kchaou A et al. Plummer-Vinson syndrome. *Tunis Med*, 2010; 88(10):721-724. PMID: 20890819.
20. Wahid FI, Hussain M, Khan A, Khan IA. Frequency of hypopharyngeal carcinoma in patients presenting with dysphagia. *Pak J Surg*, 2012; 28(1):17-20