

# Efficacy Of Vocal Cord Medialization by Injection Thyroplasty Using Liquid Paraffin In Relieving Hoarseness Of Voice In Idiopathic And Traumatic Unilateral Vocal Cord Paralysis

Muhammad Saleem<sup>1</sup>, Muhammad Sarim Khan<sup>2</sup>, Ashar Alamgir<sup>3</sup>, Muhammad Hamza Rana<sup>4</sup>, Hafiz Sajjad Hyder<sup>5</sup>, Syeda Jamila Ali<sup>6</sup>

## Abstract

**Objective:** The objective of the study was to measure the efficacy of injection thyroplasty by liquid paraffin in the medialization of vocal cords in permanent post-traumatic or idiopathic hoarseness.

**Methodology:** A total of 37 patients were enrolled in the study after obtaining approval from the ethical review board. The sample size was calculated using the WHO sample size calculator. All the patients in the study presented with hoarseness of voice due to either traumatic injury, idiopathic aetiology, or post-thyroidectomy. Samples were selected by simple random sampling. It was a Quasi-experimental study. All patients underwent an injection thyroplasty procedure using liquid paraffin to medialize the vocal cords. All the procedures were done under local anaesthesia. The patients were kept in follow-up for 1 year at an interval of 3 months. All the data was entered and analyzed by using SPSS version 24. Paired sample t-test was applied to measure pre-procedure and post-procedure scores.

**Results:** The mean age of the participants was 38 years. Out of 37 patients 23 (62%) patients presented within 6 months of hoarseness of voice. 14 (38%) patients presented after 6 months of hoarseness of voice. 19 out of 23 patients (83%) underwent only a single dose of liquid paraffin via injection thyroplasty to resolve hoarseness of voice. However, out of 14 patients, 7 patients (50%) reportedly had to undergo 2 doses of liquid paraffin via injection thyroplasty. The p-value calculated was <0.005 which was statistically significant. Out of patients presenting after 6 months, 11 patients (79%) underwent transcervical phonation surgery. The p-value calculated was <0.05 which is statistically significant.

**Conclusion:** Our study concludes that liquid paraffin is a safe and cost-effective solution for vocal cord paralysis. Liquid paraffin is not expensive and easily available which can be implied to yield excellent results to improve hoarseness of voice. Patients with late presentation are less likely to get the benefit of this procedure and may have to go for invasive transcervical phonation surgeries. It is recommended that this procedure should be done within 6 months of the development of hoarseness of voice.

**Keywords:** vocal cord palsy, unilateral vocal cord paralysis, laryngeal paralysis, liquid paraffin, injection thyroplasty.

<sup>1</sup> Associate Professor, Department of Otorhinolaryngology & Head Neck Surgery, Aziz Fatimah Hospital, Faisalabad; <sup>2,4</sup> House Officer, Aziz Fatimah Hospital, Faisalabad; <sup>3</sup> Assistant Professor, Department of ENT, Rawalpindi Medical University; <sup>5</sup> Assistant Professor, Department of ENT Unit 1, Faisalabad Medical University, Faisalabad; <sup>6</sup> Senior Registrar, Department of ENT, Abwa Medical College, Faisalabad.

**Correspondence:** Dr. Muhammad Hamza Rana, House Officer, Aziz Fatimah Hospital, Faisalabad. Email: thehamzacity@gmail.com

**Cite this Article:** Saleem M, Khan MS, Alamgir A, Rana MH, Hyder HS, Ali SJ. Efficacy Of Vocal Cord Medialization by Injection Thyroplasty Using Liquid Paraffin In Relieving Hoarseness Of Voice In Idiopathic And Traumatic Unilateral Vocal Cord Paralysis. JRMC. 2024 Mar. 28;28(1). <https://doi.org/10.37939/jrmc.v28i1.2310>.

Received January 19, 2023; accepted July 31, 2023; published online March 15, 2024

## 1. Introduction

Unilateral vocal cord paralysis (UVCP) is widespread in clinical practice, sometimes the cause remains undiagnosed. Unilateral vocal cord paralysis (UVCP) leads to glottic insufficiency, resulting in dysphonia, cough, aspiration, and pneumonia. Unilateral vocal cord paralysis can be due to trauma, surgery, radiation or cancer.<sup>1,2</sup> The aetiology of vocal cord immobility due to nerve injury can be iatrogenic i.e., thyroid, carotid, thoracic, or cervical spine surgery and accidental injury to vagus or recurrent laryngeal nerve. Patients with either aetiology report a significant compromise in their quality of life.<sup>2</sup>

Currently, two sets of treatment options are available for the disease. One is conservative management, including speech and voice therapy. The second one is voice reconstruction surgery which is an invasive procedure. The fundamental principle of both therapies is the adjustment and strengthening of the glottis and supraglottic sphincters elevation and stabilization of the larynx, which improves glottal adduction and intrinsic muscle strength and agility.<sup>3</sup> One of the surgical options includes injection thyroplasty, which involves the medialization of the vocal cords by inserting different materials that would help to adduct the vocal cords. A cost-minimization analysis was done to evaluate the outcomes and

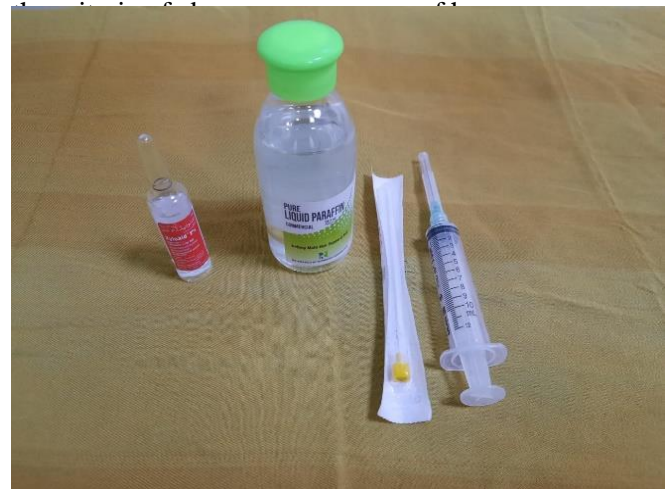efficacy of the injection thyroplasty in low to medium-resource countries. Prolene mesh implant is cost cost-effective alternative.<sup>4</sup> The added advantage of this procedure is that it can be performed with topical anaesthesia at the hospital bedside in the clinic. Unilateral vocal cord paralysis is treated by using a technique named Injection thyroplasty. Injection thyroplasty has been practised using materials such as Teflon paste and hyaluronic acid for many years.<sup>5</sup> In the old literature, liquid paraffin was used as a temporary material. The efficacy of injection thyroplasty is different in different studies as these materials injected are temporary and re-administration is required after some time. The permanent results were achieved by phonation surgery only. However, some other materials have also been used to achieve permanent results. A meta-analysis states that unilateral vocal cord paralysis treated with early injection thyroplasty medialization using a temporary material often does not require any transcervical medialization invasive procedures and results are permanent. It has been observed that patients undergoing early injection thyroplasty within six months do not usually require transcervical surgery and repeated injections. Moreover, Injection medialization has shown extensively significant results in the pediatric population.<sup>6</sup> The objective of this study was to explore the efficacy of liquid paraffin for vocal cord medialization in patients with early and late presentation of hoarseness of voice.

## 2. Materials & Methods

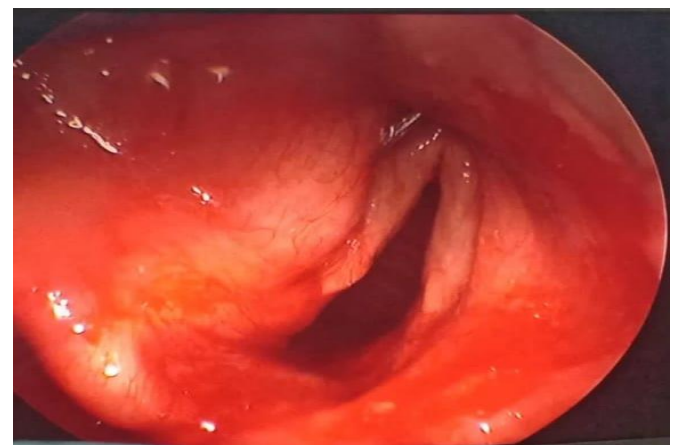Approval was taken from the Institutional Review Board (IRB) of Aziz Fatimah Medical and Dental College Faisalabad approved the study under ethical letter no. IEC/41-20. An experimental study was designed from October 10<sup>th</sup>, 2020, to November 26<sup>th</sup>, 2022, enrolling all adults of either gender with a complaint of hoarseness of voice. Moreover, only those patients were included in the study who had not undergone other treatment modalities or injection thyroplasty with material other than Liquid paraffin. Before selecting a patient for the injection thyroplasty, a brief history and clinical history were done. The patients were inspected and diagnosed with post-surgical and idiopathic unilateral vocal cord paralysis with awake endoscopy. A total of 37 patients in the study were diagnosed with Unilateral vocal cord

paralysis (UVCP). Inclusion criteria were those patients who had post-surgical idiopathic unilateral vocal cord paralysis. Vocal cord paralysis with other causes like carcinoma was excluded from the study.

Before applying local anaesthesia, the patient was asked to gargle with 4% Lidocaine to minimize cough reflex. Local anaesthesia was given at the cricothyroid membrane by visualizing the vocal cords under a flexible nasopharyngoscope. 1cc to 3cc liquid paraffin was loaded in a 10 cc syringe (Figure 1) and during injecting liquid paraffin, the vocal cords were visualized by nasopharyngoscope and the patient was advised to produce sounds to see the results of the injection (Figure 2). After the procedure, the patient was kept under observation for 2 hours. The first follow-up was done after 1 month and 2<sup>nd</sup> follow-up was done after 2 months and later one was telephonically for 2 years. The hoarseness of voice was assessed and evaluated as per



**Figure 1: Liquid paraffin, 10 cc syringe, spinal needle (actual picture taken by author)**



**Figure 2: Medialized vocal cord (actual picture taken by author)**

### 3. Results

Table 1 shows demographic details while Table 2 shows disease aetiology. Most of the patients, 18(49%), belonged to age groups ranging from 36-50 years. The mean age calculated was 38 years. The majority of the population was female, with a percentage of 21 (57%) presenting with hoarseness of voice (Figure 3) 19 patients (51%) belonged to idiopathic aetiology, and 18 patients (49%) of the patients belonged to traumatic aetiology. Figure 4 indicates the percentage of males (43%) and females (57%) participating in the study.

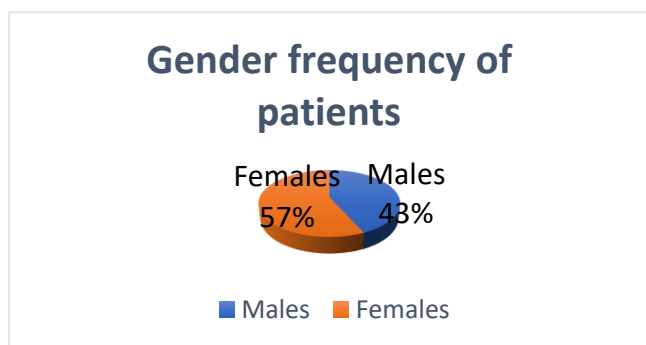
**Table 1: Demographic details**

Variable	Frequency (%)
<b>Age</b>	
20-35	14 (38%)
36-50	18 (49%)
51-65	5 (13%)

**Table 2: Aetiology of disease**

Aetiology	Frequency (%)
Idiopathic	19 (51%)
Traumatic	18 (49%)

Out of 23, 19 patients (83%) required only one dose of liquid paraffin, while 3(13%) underwent another injection at the first follow-up, and 1(4%) required a second injection to settle complete hoarseness of voice. Contrary to that, three patients(21%) out of 14 in group B underwent one dose. Four patients underwent a repeated injection thyroplasty after six months, and seven patients on the second follow-up. No patient in either group was reported to have a dose of liquid paraffin at the third and fourth follow-ups.



**Figure 3: Gender frequency of patients**

A p-value of <0.005 was calculated which was statistically significant. Outcomes of the liquid paraffin were assessed as the number of patients who underwent injection thyroplasty and permanently resolved the symptoms of hoarseness of voice.

**Table 3: Patients undergoing injection thyroplasty**

	Patients undergoing only one injection of liquid paraffin	Need of repeated injection on first follow-up (6 months)	Need of repeated injection on second follow-up (1-year)	p-Value
<b>Group A [Patients presenting in early group &lt;4 months (n=23)]</b>	19 (83%)	3 (13%)	1 (4%)	<0.005
<b>Group B [Patients presenting in late group &gt;4 months (n=14)]</b>	3 (21%)	4 (29%)	7 (50%)	

**Table 3: Outcomes of Injection Thyroplasty using liquid paraffin injection**

Outcome	Group A [Patients presenting in early group <4 months (n=23)]	Group B [Patients presenting in late group >4 months (n=14)]	p-Value
<b>Permanent Improvement of hoarseness of voice</b>	21 (91%)	3 (21.5%)	<0.05
<b>Transcervical surgery</b>	2 (9%)	11 (78.5%)	

The patients who had hoarseness of voice on the next follow-up were again selected for injection. In Group A, with the early presentation, 21 patients (91%) had permanent resolution of the hoarseness of voice, while two patients (9%) underwent transcervical phonation surgery. On the other hand, 11 patients (78.5%) underwent transcervical phonation surgery, and three patients had improvement in hoarseness of voice.

### 4. Discussion

Unilateral vocal cord paralysis (UVFP) can lead to glottic insufficiency, leading to hoarseness of voice, breathing difficulties, aspiration of the content and chronic cough, ultimately damaging the mucosa of the upper respiratory tract. Various treatment modalities have been reported to correct this aetiology.<sup>7</sup>

The results of our study suggest that medializing a paralyzed, abducted vocal cord with temporary material can permanently alter its position. A medialized vocal cord is more likely to maintain a permanent medialized position by synkinetic reinnervation than the invasive procedure. Due to the diversity of causes of denervation, anatomic injuries, and reinnervation patterns, it is admittedly difficult to determine the time window for synkinetic reinnervation. According to a study, the chronic phase of proper laryngeal nerve regeneration following a complete transection injury is 4 to 5 months, during which the regeneration begins. Hence in our study, a cut-off period of 4 months was selected before grouping the patients into two different groups.<sup>8</sup>

In our study, 19 patients (83%) underwent only one dose of liquid paraffin, while 3 (13%) and 1 (4%) with repeated injection thyroplasty with liquid paraffin on the second and third follow-ups. No hospital admission was required until a complicated anatomical or physiological challenge hindered them. A study by Akihito Hasukawa et al. stated a significant improvement in patients undergoing injection thyroplasty ( $p < 0.001$ ).<sup>9</sup>

In our study, out of 14 patients only 3 (21%) patients recovered with injection thyroplasty while 4 (29%) patients on 1<sup>st</sup> follow-up and 7 (50%) patients on 2<sup>nd</sup> follow-up. A retrospective study by Katherine C Yung reported that only 5 of 19 patients underwent phonation surgery after being treated with injection thyroplasty. It has been observed from literature evidence that agents used to relocate the vocal cords were statistically significantly less likely to undergo permanent medialization laryngoplasty. Our study advocates the advantages of using liquid paraffin as a temporary material which yields excellent results, and the patients with a follow-up of more than nine months report no need for the surgery.<sup>10</sup>

In our study, outcomes of the injection thyroplasty were assessed by comparing the patients who completely resolved hoarseness of voice with the patients undergoing transcervical phonation surgery. Only 2 patients in group A underwent transcervical phonation surgery while 11 patients in group B. The  $p$ -value  $< 0.05$  suggests the statistical significance of injection thyroplasty. Another study by Kimberly N Vinson et al. advocates the efficacy of injection thyroplasty as the participants showed significant voice improvement.<sup>11</sup>

Similar results were appreciated in the study by Morgan et al.<sup>12</sup> Different materials have been used to obtain permanent or long-term results by injection thyroplasty. Our study advocates liquid paraffin being cheaper and readily available with permanent healing results serving as a permanent material. A systematic review states that injection thyroplasty is a cost-saving and quick procedure to medialize the vocal cords.<sup>13</sup>

A single institutional study and a limited number of patients are the prime limitations of the study. A limited number of participants can certainly question the credibility of the material used. However, in our study, a very low set of participants have stated recurrence after undergoing the procedure with liquid paraffin.

## 5. Conclusion

A preliminary, experimental, observational study suggests that early vocal cord medialization injection reduces the need for open-neck laryngeal framework surgery in patients with persistent UVCP. In hospitalized patients with suspected and diagnosed injuries, bedside medialization injection may be beneficial beyond reducing aspiration risk and improving coughing and communication ability. Liquid paraffin is cheaper than other materials such as TEFLON paste, Hyaluronic acid, and other materials commonly used for injection thyroplasty. Although liquid paraffin is a temporary material, it yields permanent results in relieving patients' hoarseness. Hence, our study encourages the use of liquid paraffin in patients presenting with idiopathic and traumatic etiologies. Vocal cord medialization with liquid paraffin is a safe and cost-effective alternative to surgical intervention for treating hoarseness of voice.

**CONFLICTS OF INTEREST-** None

**Financial support:** None to report.

**Potential competing interests:** None to report

**Contributions:**

M.S - Conception of study

M.S.K, A.A - Experimentation/Study Conduction

M.S, M.S.K, M.H.R, S.J.A -

Analysis/Interpretation/Discussion

M.S.K, M.H.R, S.J.A - Manuscript Writing

M.S, A.A, M.H.R, H.S.H, S.J.A - Critical Review

A.A, H.S.H - Facilitation and Material analysis

All authors approved the final version to be published & agreed to be accountable for all aspects of the work.

## References

1. Williamson AJ, Shermetaro C. Unilateral vocal cord paralysis. StatPearls (internet). Treasure Island (FL): StatPearls Publishing; 2023.
2. Akhtar MU, Bashir S, Hassan ZU, Maka TA, Akhtar MS, Razzaq S. Vocal cord paralysis: What matters between Idiopathic and Non-idiopathic cases? Pak Armed Forces Medical Journal. 2017;67(6):943-7.
3. Alghonaim Y, Roskies M, Kost K, Young J. Evaluating the timing of injection laryngoplasty for vocal fold paralysis in an attempt to avoid future type 1 thyroplasty. Journal of Otolaryngology-Head & Neck Surgery. 2013;42(1):24. DOI:10.1186/1916-0216-42-24.
4. Rashid M, Karim MN, Saleem H, Najam A, Aasim U, Hashmi MA, et al. A novel technique for Thyroplasty type 1, with Prolene mesh implant. Journal of Voice. 2021 Oct 24. DOI:10.1016/j.jvoice.2021.09.015.
5. Tam S, Sun H, Sarma S, Siu J, Fung K, Sowerby L. Medialization thyroplasty versus injection laryngoplasty: A cost minimization analysis. Journal of Otolaryngology - Head & Neck Surgery. 2017;46(1):14. DOI:10.1186/s40463-017-0191-5.
6. Perazzo PSL, Duprat A de C, Lancellotti CLP. Histological Behavior of the Vocal Fold After Hyaluronic Acid Injection. Journal of Voice. 2009;23(1):95–8.
7. Vila PM, Bhatt NK, Paniello RC. Early-injection laryngoplasty may lower risk of thyroplasty: A systematic review and meta-analysis. Laryngoscope. 2018;128(4):935–40. DOI:10.1002/lary.26894.
8. Modi VK. Vocal fold injection medialization laryngoplasty. Advances in Otorhinolaryngology. 2012;73:90–4.
9. Friedman AD, Burns JA, Heaton JT, Zeitels SM. Early versus late injection medialization for unilateral vocal cord paralysis. Laryngoscope. 2010;120(10):2042–6.
10. Hasukawa A, Mochizuki R, Sakamoto H, Shibano A, Kitahara T. Surgical effects of type-I thyroplasty and fat injection laryngoplasty on voice recovery. Auris Nasus Larynx. 2021;48(2):302–9.
11. KS, Ryu CH, Kwon TK, Kim H, Kim HS, Park IS, et al. Guidelines for the management of unilateral vocal fold paralysis from the Korean Society of Laryngology, Phoniatrics and Logopedics. Clinical and experimental otorhinolaryngology. 2020 Nov;13(4):340. DOI:10.21053/ceo.2020.00409
12. Vinson KN, Zraick RI, Ragland FJ. Injection versus medialization laryngoplasty for the treatment of unilateral vocal fold paralysis: follow-up at six months. Laryngoscope. 2010;120(9):1802–7.
13. Kim GH, Lee JS, Lee CY, Lee YW, Bae IH, Park HJ, et al. Effects of injection laryngoplasty with hyaluronic acid in patients with vocal fold paralysis. Osong Public Health and Research Perspectives. 2018 Dec;9(6):354.61.
14. Wan-Chiew N, Baki MM, Fauzi MB, Lokanathan Y, Azman M. In Vitro Evaluation of Biomaterials for Vocal Fold Injection: A Systematic Review. Polymers (Basel). 2021;13(16):2619. DOI:10.3390/polym13162619.