

Quantitative Comparison of Mast cells in Major Salivary Glands in Hypothyroid State

Nida Qasim Hayat¹, Shahnaila Nadir², Ansa Rabia³

1.Department of Anatomy, University of Health Sciences, Lahore;2.Department of Anatomy, Women Medical College, Abbottabad;3.Department of Anatomy, CMH, Lahore Medical College, Lahore.

Abstract

Background: This experimental study was carried out to compare the number of mast cells in major salivary glands of albino rat in hypothyroid state.

Methods: An experimental study was carried out on twenty male albino rats, weighing between 130-150 grams. The rats were divided into two groups; control group (A) and an experimental group (B), with 10 animals in each group. Hypothyroid condition was modeled in albino rats of experimental group (B) by giving them 0.02% w/v Methimazole (MMI) for three weeks in drinking water. After 4-weeks animals from both the groups were euthanized with chloroform. The blood sample was taken from each rat for determination of thyroid hormone concentrations in the serum by cardiac puncture. Serum T₃, T₄ and TSH levels were determined by enzyme immunoassay to confirm hypothyroid state of the animal. Major salivary glands; parotid, submandibular and sublingual were dissected and removed from the body. They were fixed in Bouin's solution. Glands were further processed for light microscopy and for histological analysis of mast cells Toluidine blue stain was used. Counting of mast cells (MCs) was performed by superimposing the ocular graticule on the salivary gland preparation.

Results: Statistically significant difference was observed between the MCs of parotid gland in group A (2.25±1.34/mm²) and B (3.70±1.11/mm²), p<0.017. No significant difference was observed in the mean number of MCs in the sublingual and submandibular salivary glands with p=0.511 and p=0.187 respectively.

Conclusion: In hypothyroid state, there is significant difference in the number of MCs in the parotid glands and there is no significant difference in the number of MCs of submandibular and sublingual glands.

Key Words: Mast cells, Salivary glands, Hypothyroidism, Methimazole (MMI)

Introduction

Mast cells (MCs) are leukocytes originating from haematopoietic progenitor cells. Initially circulating in the blood in an immature form they reach their final maturation after they migrate to vascularised tissues with the help of stem-cell factor and other cytokines. Endothelial cells and fibroblasts secrete these cytokines.¹⁻³

MCs have been implicated in many immune-inflammatory disorders.^{2,4,5} Being multifunctional they play a cardinal role in innate and adaptive immunity against microbial infections along with initiating IgE dependant allergic diseases.⁶ MCs are ideally located to participate in the early recognition of the pathogens specifically in areas that are in close contact with the external environment.^{3,6} They are located strategically at host/environment interfaces like skin, airways, gastrointestinal and urogenital tracts. MCs also populate connective tissue in association with blood and lymphatic vessels and nerves.⁷ They play a leading role in inflammatory processes, allergic reactions and in autoimmune disease pathogenesis since they produce various cytokines.^{1,5} MCs having different locations have numerous histochemical, cytochemical, ultra structural, and functional properties.⁸ They are also thought to play a role in angiogenesis, tissue remodelling, wound healing, and tumour repression or growth. Due to their phenotypic adaptability to different tissue micro-environment and their ability to generate and release a diverse array of bioactive mediators in response to multiple types of cell surface and cytosolic receptors they elicit both physiologic and pathologic role owing to their flexible nature.⁹

MC distribution has shown to be altered in various fibroproliferative disorders like pterygium, wound healing and rhinoscleroma.² Prominent increase in MCs was observed in lesions of breast like mammary dysplasia, fibroadenoma and scirrhous carcinoma of breast.² Various salivary gland conditions as sialadenitis, pleomorphic adenoma and

cystadenolymphoma showed increased number of degranulating mast cells as well.²

Pathological MCs can accumulate in potentially any or all organs and tissues and result in aberrant release of variable subsets of mast cell mediators resulting in mast cell activation disease (MCAD). Disorders of thyroid gland is one of the disease which should be considered as differential diagnosis of mast cell activation disease since they mimic or may be associated with mast cell activation.¹⁰ MCs influence thyroid function; treatment with disodium cromoglycate (mast cells stabilizer) partially blocked the TSH actions on thyroid gland, thus evidencing that thyroidal mast cells act as an intermediary factor of TSH actions on thyroid gland. Furthermore, both T3 and T4 concentrations were increased after compound BW48-80 (mast cell disrupter polymer), which confirmed the active participation of mast cells on TSH secretion.¹¹

Histological analysis of thyroid gland in methimazole-induced hypothyroid rat revealed MCs in the vicinity of the capillaries and stroma of hypertrophic connective tissue.¹² Increase in amount of MCs was also documented in hypothyroid female skin when experimental group was compared to the control.¹ MCs further detect events in mediator cascade and this is why quantity of mast cells increased in maternal hypothyroidism¹. Number of MCs were significantly increased in sublingual gland of hypothyroid rat 6-weeks after thyroidectomy indicating a pathology in the gland.¹ Therefore increased MCs are associated with different pathological conditions, but the functional significance of these cells in the pathological processes is mostly unknown.

One of the most frequent thyroid disorder in humans is hypothyroidism in which production of the thyroid hormones decreases below the normal level.¹² The hypothyroid state is a complex hormonal dysfunction rather than a single hormonal defect, manifested largely by a reversible slowing down of all body functions^{13,14}. In 1989, it was reported that enlarged salivary glands were common in patients with hypothyroidism (myxoedema), but this finding was not widely accepted. It had been suggested that parotid, submandibular and in particular the sublingual gland were discernibly enlarged and served as a useful clue to the diagnosis of hypothyroidism.¹⁵

Regarding their morphology, histochemistry and ultra structure, the salivary glands of rats had been the subject of immense interest for researchers. The histological aspects of salivary glands had not been

sufficiently studied in hypothyroid state though investigations regarding its physiological and biochemical effects received sufficient attention.^{16,17}

A correlation existed between autoimmune thyroiditis and salivary gland dysfunction / Sjögren's syndrome^{18,19}. Sjogren's syndrome and hypothyroidism both resulted in xerostomia.¹⁸ In Sjögren's syndrome, salivary glands gradually become filled with inflammatory cells. Mast cells were previously studied by metachromatic toluidine blue staining of labial salivary glands where study showed that number of mast cells was higher in patients than in healthy controls.⁴

Any alterations in the integrity and activity of the salivary glands can change salivary flow and its composition, thus affecting patient's nutritional intake causing additional stress and depression. Therefore, the research on the salivary glands has not only significant medical but also social implications.

Histological analysis of the salivary glands after administration of a variety of drugs and pathological conditions had been illustrated in a number of studies, but it is evident that information about the presence or absence of MCs in salivary glands in hypothyroid state is insufficient.²⁰⁻²²

Material and Methods

Twenty male Albino rats, 42-60 days old, weighing between 130-150 grams were procured from the National Institute of Health, Islamabad. All the animals were examined thoroughly for health status before the commencement of the experiment. The rats were housed in the Research laboratory of University of Health Sciences, Lahore under controlled conditions of temperature $22 \pm 0.5^\circ\text{C}$, humidity $50 \pm 10\%$, 12 hours light/dark cycle; and the animals were fed on rat chow, tap water ad libitum and were acclimatized for a period of one week. Twenty male Albino rats were divided into two groups of 10 each; Group A served as control whereas Group B was used as an experimental group. Hypothyroid condition was modeled in Albino rats by giving them 0.02% w/v Methimazole (MMI) for three weeks in drinking water; one full feeding bottle was consumed daily. Fresh solution of MMI was prepared daily. Control group received distilled water only. After 4-weeks animals from both groups were euthanized with chloroform. The blood sample was taken from the rat for determination of thyroid hormone concentrations in the serum obtained in a usual way from 6 ml of blood taken in 10 ml disposable syringe by cardiac puncture.

Total serum T₃, T₄ and TSH concentrations were determined by using commercially available enzyme Immunoassay test kits (procured from Bio Check, Inc 323 Vintage Park, dr. Foster City, CA 94404). Each animal was killed under anaesthesia, the salivary glands were removed. A transverse incision was given in the upper part of the neck, skin was carefully reflected in the neck and one side of the face to reveal these glands. Glands were carefully dissected and removed in one piece and were fixed it in Bouin's fluid¹². The fixed tissues were processed in automatic tissue processor with different strengths of alcohol and cleared in xylene. The tissue pieces were embedded in paraffin wax and 5µm thick sections were obtained using a rotary microtome (Leica RM 2125). Glass slides with tissue specimen was stain with toluidine blue. The identification of mast cells with metachromatic granules was done by special stain 1% aqueous toluidine blue. The solution of toluidine was prepared by dissolving 1gm of toluidine blue powder into 100ml of distilled water for 1 minute and PH was adjusted to 4. The solution was filtered before use. The slides were rinsed in water, dehydrated in absolute alcohol, cleared in xylene and mounted on DPX. The slides were seen using light microscope (Leica DM 1000). Mast cell granules stained purple and background tissue stained blue.

Counting the number of MSc with Graticule: Paraffin sections stained with toluidine blue were used to determine the number and distribution of mast cells in the salivary glands using light microscope (Leica, DM 1000). X40 objective was used for calibrating ocular graticule. Ten areas from each slide were randomly selected and mast cells were counted at X400 magnification. MCS in the control salivary gland specimens were counted and compared with mast cells in salivary glands after being rendered hypothyroid. An eyepiece graticule (0.0625mm²) was used in order to avoid overlapping of counting areas. Areas selected in each region were surveyed for mast cells and the mast cell density was then expressed as cell number per unit area. 20 x 20 squares (area = 1mm²) grid eyepiece graticule engraved on a disc, was placed inside the eyepiece of the microscope. Stage micrometer, a 3 x 1 inch slide on which 1 mm scale divided into 100 equal divisions is engraved, was placed under the objective. X 40 objective was selected and focused on the stage micrometer scale. Number of transverse and vertical segments of ocular graticule squares equal to an exact number of divisions of stage micrometer scale was determined.

As each 4 transverse and vertical segments of ocular graticule squares were equal to 5 stage divisions, therefore:


$$100 \text{ stage divisions} = 1\text{mm} = 1000 \mu\text{m}$$

$$1 \text{ stage division} = 1000 / 100 = 10 \mu\text{m}$$

$$4 \text{ segments of graticule} = 5 \text{ stage divisions or } 5 \times 10 = 50 \mu\text{m}$$

$$1 \text{ segment of graticule} = 50 / 4 = 12.50 \mu\text{m}$$

Area of graticule was calculated by multiplying the calibrated factor 12.50 with transverse and vertical segments of 20 small squares of the graticule as follows:



$$(20 \times 12.50 = 250 \mu\text{m or } 0.25\text{mm}) \times (20 \times 12.50 = 250 \mu\text{m or } 0.25\text{mm}) \text{ Or } 0.25 \times 0.25 = 0.0625 \text{ mm}^2$$

As the counting was done in 10 randomly selected fields at X 400 magnification; avoiding overlapping, the total area per section was therefore, calculated as 0.0625 x 10= 0.625mm². Counting of mast cells was performed by superimposing the ocular graticule on the salivary gland preparation; the cells were counted irrespective of their size but excluding those lying on the upper and right edges of the graticule squares to avoid counting them more than once. The data was entered and analyzed using SPSS 21.0. Mean ± S.D was given for normally distributed quantitative variables. A p-value < 0.05 was considered as statistically significant.

Results

Statistically significant difference was observed between the mast cells of parotid gland in group A (2.25±1.34/mm²) and B (3.70±1.11/mm²), p<0.017 (Table.1). However, no significant difference was observed in the mean number of mast cells in the sublingual and submandibular salivary glands with p=0.511 and p=0.187 respectively (Table. 1). Mast cells in sections stained with Toluidine blue had various size and appearance. They were flat, round or oval shaped. Light microscope revealed homogenous cytoplasm rather than having a granular appearance. It was found that mast cells were predominant near

blood vessels within the interlobular connective tissue. However, they were also found in the intralobular connective tissue around the secretory acini (Fig 1 &2). Light microscope revealed homogenous cytoplasm rather than having a granular appearance. It was found that mast cells were predominant near blood vessels within the interlobular connective tissue. However, they were also found in the intralobular connective tissue around the secretory acini.

Table. 1: Comparison of the mean number of mast cells in salivary glands in groups A & B.

	Number of mast cells (number/mm ²)		
	Sublingual gland	Submandibular gland Mean ±	Parotid gland Mean ± S.D
Group A	1.30±0.85	2.33±1.34	2.25±1.34
Group B	1.53±0.67	3.02±0.84	3.70±1.11
P-value	=0.511	=0.187	<0.017*

*p value < 0.05 is statistically significant

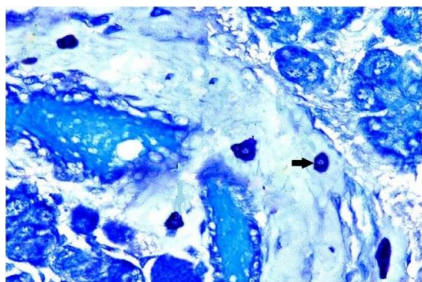


Fig. 1. Parotid gland (Group A): Mast cells (arrows) are present within the connective tissue. Toluidine blue stain. X 400.

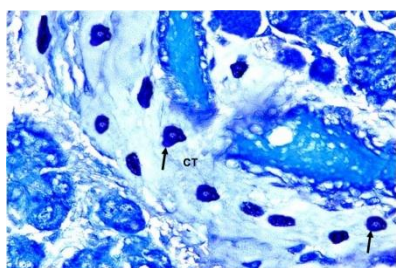


Fig. 2. Parotid gland (Group B): Mast cells (arrows) are abundantly present within the connective tissue (CT). Toluidine blue stain. X 400.

Discussion

In previous experimental studies on animal models, thyroid gland was successfully rendered hypo-functional upon treating it with MMI.^{12,24-26} The functional state of thyroid gland was established by serum levels of T₃, T₄ and TSH hormones.¹² In our experimental model, development of hypothyroidism was confirmed by changes in the T₃, T₄ and TSH serum

levels. Significant decrease in T₃, T₄ and increase in TSH serum levels was indicative that the quantity and duration of treatment was sufficient to induce hypothyroid status in the experimental group of rats.

Heterogenicity of mast cells in a variety of organs had been reported earlier.^{8,27} Additionally, it contributes to the process through production of histamine, heparin and tryptase. Increase of MCs is associated with different pathological conditions, such as chronic inflammatory processes, fibrotic disorders, wound healing and neoplastic tissue transformation, but the functional significance of the accumulation of mast cells in these processes is mostly unknown²⁸. It had been established that bone-marrow-derived mast cells progenitors circulate in the peripheral blood which subsequently migrate into the tissues where they undergo final maturation under the influence of local micro environmental factors. Oncu *et al* (2004) reported significantly increased number of mast cells 6-weeks after thyroidectomy in the sublingual gland. In the current investigations we found there is a statistically significant increase (p<0.017) in the number of mast cells in parotid gland when the control group was compared with that of the experimental¹³. Whereas, the difference in number of mast cells between the control and experimental groups was statistically insignificant as for the submandibular and sublingual glands respectively. This might be due to the fact that parotid gland was most affected in hypo-functioning thyroid. Regarding sublingual gland, our findings were not in accord with those observed by Oncu *et al* (2004) who reported an increase in the number of mast cells; this could possibly be explained that the duration of experiment by Oncu was nearly twice as long as in our case.¹³

The main reason of most of the organ damage associated with hypothyroidism is decreased synthesis of number of cellular enzymes associated with thyroid hormone deficiency.³ MCs through production of various cytokines play a leading role in inflammatory processes and in autoimmune diseases pathogenesis²⁸.

Conclusion

Due to hypothyroidism, the increase in mast cells is observed in different salivary glands in which most significant is parotid gland.

References

1. Strus K, Yashchenko A, Smolkova O, Nakonechna O. Influence of maternal experimental hypothyroidism on quantitative-qualitative indicator of rat progeny skin mast cells in age aspect according to histochemical investigation results and on the base of lectins GNA and PNA receptors cytotopography. *Adv Biosci Biotechnol* 2013;4:840-45.

2. Seema V and Pattankar VL. Mast cell distribution in some commonly encountered benign and malignant salivary gland neoplasms. *IJABPT*2011;2(3):322-29.
3. Mirjam URB, Sheppard DC. The role of mast cells in the defence against pathogens. *PLoS Pathogens*. 2012;8(4):1-6.
4. Konttinen YT, Hietanen J, Virtanen I, Ma J. Mast cell derangement in salivary glands in patients with Sjögren's syndrome. *Rheumatol Int*. 2000; 19(4): 141-47.
5. Konttinen YT, Tuominen S, Segerberg-Konttinen M. Mast cells in the labial salivary glands of patients with Sjögren's syndrome: a histochemical, immunohistochemical and electron microscopical study. *Ann Rheum Dis*. 1990;49: 685- 89.
6. Lateef HAE. Mast cell activation disease. *Egypt J Pediatr Allergy Immunol*. 2013;11(2):53-61.
7. Ribatti D and Crivellato E. The role of mast cell in tissue morphogenesis. Thymus, duodenum and mammary glands as examples. *Exp Cell Res* 2015; 10:1016-19.
8. Karaca T and Yoruk M. A morphological and histometrical study on distribution and heterogeneity of mast cells of chicken's and quail's digestive tract. *YYU Vet Derg*. 2004;15(1-2):115-21.
9. Gilfillan AM and Beaven MA. Regulation of mast cell responses in health and disease. *Crit Rev Immunol*. 2011;31(6):475-79.
10. Molderings G, Brettner S, Homann J, Afrin LB. Mast cell activation disease: a concise practical guide for diagnostic workup and therapeutic options. *J Hematol Oncol*. 2011;4(10):1-8.
11. Bianco AC, Nunes MT, Douglas CR. Influence of mast cells on thyroid function. *Endocrinol Exp*. 1983;17(2):99-106.
12. Milosevic M, Korac A, Davidovic V. Methimazole-induced hypothyroidism in rats: Effects on body weight and histological characteristics of thyroid gland. *Jugoslav Med Biochem* 2004;23(2):143-47.
13. Oncu M, Kanter M, Gokcimen A, Kavakli D, Oncu M. Effect of thyroidectomy on the histology of rat sublingual gland. *APMIS* 2004;112:119-22.
14. Greenspan FS, Dong BJ. Thyroid and anti-thyroid drugs. In: Katzung BG, editor. *Basic and clinical pharmacology*. 9thed. USA: Mc Graw Hill; 2004. 625-40.
15. Fulop M. Pouting Sublinguals: Enlarged Salivary Glands in Myxoedema. *Lancet* 1989; 550-51.
16. Tanaka K and Imura H. Iodothyronine 5'-deiodinase is present in mouse sublingual gland. *Endocrinology* 1993;132(3):1195-98.
17. Hiramatsu M, Kashimata M, Kumegawa M, Minami N. Suppression by thyroid hormones of glucosamine-6-phosphate synthetase activity in rat sublingual glands. *Arch Oral Biol* 1984;29(10):849-51.
18. Coll J, Anglada J, Tomas S, Reth P, Goday A, Millan M et al. High prevalence of subclinical sjogren's syndrome features in patients with autoimmune thyroid disease . *J Rheumatol* 1997;24(9):1719-24.
19. Hansen BU, Ericsson UB, Henricsson V, Larsson A. Autoimmune thyroiditis and primary sjogren's syndrome: clinical and laboratory evidence of the coexistence of the two diseases. *Clin Exp Rheumatol* 1991;9(2):137-41.
20. Ogilvie AL. Histological findings in the salivary glands of the rat following sodium fluoride administration. *J D Res* 1951;30(5):712-27.
21. Ashour MA. Long-term effect of melatonin on submandibular salivary glands in old rats. *Eastern Mediterranean Health J* 1998;4(2):324-31.
22. Ewens AD, Mihich E, Ehrke MJ. Fluorouracil plus leucovorin induces submandibular salivary gland enlargement in rats. *Toxicologic Pathology* 2005;33(4):507-15.
23. Ozen A, Ergun L, Ergun E, Simsek N. Morphological studies on Ovarian Mast Cells in the Cow. *Turk J Vet Anim Sci* 2007; 31(2): 131-36.
24. Bhargava HN, Ramarao P, Gulati A. Effect of methimazole-induced hypothyroidism on multiple opioid receptors in rat brain regions. *Pharmacology* 1988;37(6):356-64.
25. Isman CA, Yegen BC, Alican I. Methimazole-induced hypothyroidism in rats ameliorates oxidative injury in experimental colitis. *J Endocr* 2003; 177: 471-76.
26. Kala N, Ravisankar B, Govindarajulu P, Aruldas MM. Impact of foetal-onset hypothyroidism on the epididymis of mature rats. *Int J Androl* 2002;25(3):139-48.
27. Saglam B, Cikler E, Zeybek A, Cetinel S, Ercan F. Protective effects of 2-Mercaptoethane Sulfonate (MESNA) on Protamine Sulfate induced bladder damage. *Marmara Medical J* 2005; 18(1):6-12.
28. Bischoff SC, Selge G. Mast Cell hyperplasia: role of cytokines. *Int Arch Allergy Immunol* 2002; 127: 118-22.