

Effects of Mobile Phone Induced Electromagnetic Field on Height of Follicular Cells in Thyroid Gland of Mice

Farheen Shaukat, Khadija Qamar, Shadab Ahmed Butt.

Army Medical College Rawalpindi.

Abstract

Background: To study the effects of electromagnetic radiations generated by mobile phone on height of follicular cells in thyroid gland of mice.

Methods: In this experimental study, 20 adult BALB/C male mice were divided randomly into two groups, comprising of 10 animals in each group. Group A was kept under same experimental conditions without mobile phone exposure, group B received 50 missed calls /day, from mobile phone set. Thyroid gland was removed 24 hours after the last experimental day. These were then processed and analyzed.

Results: There was significant difference in mean height of follicular epithelium in thyroid gland of control and experimental group.

Conclusion: Long term exposure to electro magnetic fields (EMFs) causes increase in size of follicular cells of thyroid gland of mice.

Key Words: Electromagnetic field , mobile phone; follicular thyroid cells

large number of base station antennas are required to provide widespread availability of service to the population. In addition to the time spent by the user on the mobile phone, there is a continuous bombardment of environmental electromagnetic fields (EMF) from base stations, which are now casually stationed in residential areas.⁴ Being waves, EMF have the inherent property of oscillation. The biological electrical activities of the human body are vulnerable to interference from the oscillatory aspects of EMF, causing subtle non-thermal effects on fundamental cellular activities.⁵ Non thermal effects of EMF have been reported in various studies. These include cell kinetics and proliferation effects, effects on cell protein, production of free oxygen radicals and nerve cell damage in mammalian brain and effects on chick embryo retina.⁶⁻⁹ In contrast to the above mentioned studies, there are also authors who contest the adverse health effects of EMF. Some researchers are convinced that there are no measurable EMF associated changes.¹⁰

Introduction

Electromagnetic radiations are emitted by many natural and man made sources and are a part and parcel of our lives. The source of electromagnetic radiation is accelerating charges, and electromagnetic radiation manifests itself as oscillating electric and magnetic field.¹ Until recently, the natural electromagnetic background was relatively constant, but situation changed markedly and precipitously with the development of modern communications and electrical power systems. The environment is now heavily laden with man made electromagnetic fields from radio, TV, microwave, mobile and many similar sources.²

Our mind, body and control of our endocrine glands and immune system are controlled by weak electrical brain waves that interact with electromagnetic environment.³ Mobile phone handsets operate in close proximity to the human body, and

Thyroid follicle is the structural unit of thyroid gland. It has roughly spherical cyst like compartments with a wall formed by a simple cuboidal or low columnar epithelium, the follicular epithelium. Hundreds of thousands of follicles that vary in diameter from 0.2 to 1.0mm constitute nearly entire mass of thyroid gland. Follicles contain gel like mass called colloid. Apical surface of follicular cells is in contact with colloid and its basal surface rest on the basement membrane.¹¹

The structural components of the thyroid gland respond to many types of stimuli and are in a state of regular adaptation in size and shape of the follicles; their content and height of the epithelium vary with the functional condition of the gland.¹¹ Any physiological change or stress is reflected in transient hyperplasia of the thyroid epithelium and reversibly involution occurs and follicular cells resume their normal size, when stress abates.

Materials and Methods

The study was carried out in department of Anatomy, Army Medical College and National Institute of Health, Islamabad from November 2009 to November 2010.

Twenty adult BALB/C male mice were taken. Animals were given standard diet and kept at standard temperature 21 ± 20 °C, and animal room was maintained on 12 hour light/dark cycle. They were divided randomly into two study groups, comprising of 10 animals in each group.

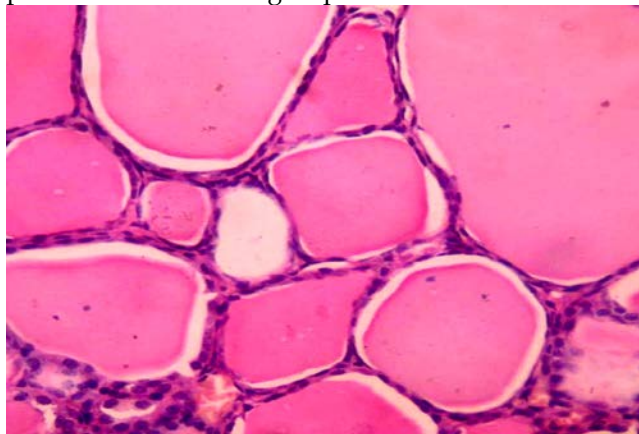
Experimental animals were housed in the standard plastic cage with the exposure device (mobile phone) kept in centre of the animal cage, in a separate small cage. Group A (Control Group) were kept under same experimental conditions without a mobile phone throughout 60 days. Group B were exposed to 50 missed calls of thirty seconds duration separated by fifteen second interval / day for 8 weeks from a GSM mobile (900/1800MHz) in silent mode .¹² At the end of experiment, animals were sacrificed by over dose of ether. Midline incision was given in neck, overlying muscles, lymph nodes and salivary glands were removed. Thyroid gland was taken out along with trachea and esophagus. Tissue was preserved in 10 percent formaline, for forty-eight hours then taken and processed for paraffin embedding, 5µm thin sections of tissue were prepared and mounted, on glass slides. Haematoxylin eosin stain was used. Sections of thyroid were examined microscopically for height of follicular epithelium under high power field.

For the calculation of height of follicular epithelium, an ocular micrometer was used in calibration with a standard stage micrometer. Three observations were made in each lobe of gland in this way with six observations in each section and 60 observations in each group. Descriptive statistics were used to describe the data, i.e., mean and standard error(SE) for follicular epithelial height (ANOVA) followed by Post_hoc tukey test. The difference was regarded statistically significant if the p value was equal to or less than 0.05. p value was found by means of "t" distribution table.

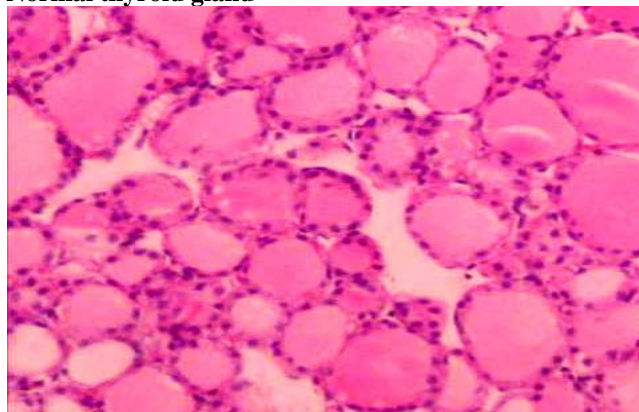
Results

Findings of group A (Control):On microscopic examination thyroid gland revealed normal morphology. The thyroid gland of control animals was characterized by the predominance of macrofollicles rich in a colloid material. Mean height of follicular

epithelium was $3.60 \pm 0.12\mu\text{m}$. Thyroid follicles were lying in close approximation with little stroma in between. and surrounding area of follicle showed parafollicular cells in groups and blood vessels.



Normal thyroid gland



Experimental thyroid

Fig1: Low power view of normal (A) and experimental (B) thyroid

Findings of group B (Experimental):Whereas the lobes in the exposed group showed numerous micro follicles with less colloid content, mean height of follicular epithelium was $7.26\mu\text{m} \pm 0.24\mu\text{m}$. The thyroid stroma in exposed mice consisted of wider connective tissue septa and more dilated blood capillaries compared with those of the controls

Table1:Epithelial height of both groups

Groups	Mean±SE(µm)
Control group A	3.60 ± 0.12
Experimental group B	7.26 ± 0.24
P-Value	<0.00*

* Highly significant

Discussion

In past few years, the increased use of personal mobile phones have worried users because of the position of transmitter close to the users head. Faced with the urgent question of whether mobile telephones are harmless, many studies have been carried out to evaluate possible effect of EMFs on the tissues.¹³ Duration of exposure to the cellular phone is an important factor, but the exact duration differs from individual to individual. Today mobile telephone work at the total power output of about two watts, are estimated to produce insignificant local heating, which is unlikely to produce any deleterious effects.¹⁴ Recent research suggest that there are non thermal effects on the living tissue. The cell receptors respond to the carrier signal of the mobile phone, and get excited resulting in the impairment of delicate microtubular connections between the cells; in other words the cells get locked up. Furthermore this leads to an increase in intracellular heavy metals and reactive oxygen species (ROS) generation. ROS play a major role in electromagnetic radiation induced tissue damage.¹⁵ Exposure to 900MHz electromagnetic radiations from mobile phone has been shown to increase malondialdehyde, nitric oxide levels and activities of xanthine oxidase and glutathione peroxidase and to decrease the activity rate of superoxide dismutase and glutathione peroxidase activities in the rat brain.¹⁶ Exposure of adult Spargue-Dawely rats to regular cell phones also resulted in mRNA up regulation of several injury associated proteins such as calcium.¹⁷

References

1. Mcnamee JF, Pascale.V. Cytogenic and carcinogenic effects of exposure to radiofrequency radiation. Springer-Verlag,2007; 28:427-447.
2. Hashish,AH, Missiry, M, A., Abdelkader H.I., Abou-Saleh R.H. Assessment of biological changes of continuous whole body exposure to static magnetic field and extremely low frequency electromagnetic fields in mice. *Ecotoxicology and Environmental Safety*, 2008; 71: 895-902.
3. Saunders,T. Health hazards and electromagnetic field. *Complementary Therapies in Nursing & Midwifery*, 2003; 9: 191-201
4. Zareen,N., Yunus,M,K., Minhas,L,A. Derangement of chick embryo retinal differentiation caused by radiofrequency electromagnetic fields. *Congenital Anomalies*, 2009; 49: 15-19.
5. Blank M. Do electromagnetic fields interact with electrons in the Na,KATPase? *Bioelectromagnetics*, 2005 26: 677-683.
6. Velizarov S, Raskmark P, Kwee S. The effects of radiofrequency fields on cell proliferation are non-thermal. *Bioelectrochem Bioenerg*, 1999; 48:177-180
7. Friedman, J., Kraus, S., Hauptmann, Y., Schiff, Y., and Rony, S. Mechanism of short term ERK activation by electromagnetic fields at mobile phone frequencies. *Biochem*, 2007; 405: 559-568.
8. Eraslan, G., Bilgili, A., Akdogan, M., and Yarsan, E. Studies on antioxidant enzymes in mice exposed to pulsed electromagnetic fields. *Ecotoxicology and Environmental Safety*, 2005; 66: 287-289.
9. Salford LG, Brun AE, Eberhardt JL. Nerve cell damage in mammalian brain after exposure to microwaves from GSM mobile phones, *Environ. Health Perspect.* 111,2003; 881-883.
10. Kizilay A, Ozturan O, Erdem T, Kalcioğlu MT, Miman MT. Effects of chronic exposure of electromagnetic fields from mobile phones on hearing in rats. *Auris Nasus Larynx*, 2003; 30: 239-245.
11. Ross MH, Pawlina W. *Histology: a text and atlas with correlated cell and molecular biology*. 5th ed. Baltimore: Lippincott Williams & Wilkins; 2006. 700-04.
12. Naduvil S, Suresh R, Kumar B, Nayak S, Mailankot M. Spatial memory performance of wistar rats exposed to mobile phone. *Clinics*, 2009;64(3):231-234.
13. Irmak MK, Fadillioglu E, Gulec M. Effects of electromagnetic radiation from a cellular telephone on the oxidant and antioxidant levels in rabbits. *Cell Biochem Funct*, 2002;20:279-283. 11.
14. İlhan A, Gurel A, Armutcu F. Ginkgo biloba prevents mobile phone-induced oxidative stress in rat brain. *Clin Chim Acta*, 2004; ;340:153-162.
15. Irmak MK, Oztas E, Yagmurca M, Fadillioglu E, Bakir B. Effects of electromagnetic radiation from a cellular telephone on epidermal Merkel cells. *J Cutan Pathol*, 2003;30:135-138.
16. Joubert V, Bourthoumieu S, Leveque P, Yardin C. Apoptosis is induced by radiofrequency fields through the caspase independent mitochondrial pathway in cortical neurons. *Radiat Res*, 2008;169(1):38-45.
17. Yan JG, Agresti M, Zhang LL, Yan Y, Matloub HS. Upregulation of messenger RNA levels in rat brain after cell phone exposure. *Electromagn Biol Med*, 2008 ;27(2):147-54.