

# Esophagoscopy in the early detection and treatment of Plummer Vinson Syndrome

Muhammad Aslam Chaudhry, Ashar Alamgir, . Amjad Obaid

Department of ENT, Rawalpindi General Hospital and Rawalpindi Medical College, Rawalpindi.

## Abstract

**Background:** To determine the role of esophagoscopy as a safe and cost-effective procedure which can be used for early diagnosis and treatment of Plummer Vinson Syndrome and prevent development of carcinoma of post-cricoid area.

**Methods:** The study was carried out in E.N.T. department, Rawalpindi General Hospital, Rawalpindi. A total of 25 patients diagnosed with Plummer Vinson Syndrome presented to our department from July 2005 to June 2007 of which 23 patients were included in the study. 2 female patients were found to have carcinoma of hypopharynx and were excluded from the study. Blood CP, serum iron, barium swallow, esophagoscopy and biopsy was done in all the patients.

**Results:** The ratio between female and male was found to be 10:1. Mean hemoglobin was 8 gm/dl. Average mean corpuscular volume (MCV) was 68.5%. Serum iron level was less than 40 ug/dl in females and less than 65 ug/dl in males. Web was seen on barium swallow in all the patients and was confirmed on esophagoscopy. Biopsy of esophageal web was taken in all patients. Biopsy of 2 female patients turned out to be squamous cell carcinoma of post-cricoid region while other 21 biopsies showed normal esophageal mucosa.

**Conclusion:** Plummer Vinson Syndrome is still a common condition in females. Esophagoscopy, excision and dilatation of the web and iron replacement is safe and cost-effective procedure to diagnose and treat the disease. If untreated, may lead to serious complications like post-cricoid carcinoma.

**Key words:** Esophageal web, Plummer Vinson Syndrome, esophagoscopy, excision of web, squamous cell carcinoma.

## Introduction

The association of post-cricoid dysphagia,

upper esophageal web and iron deficiency anemia is known as Plummer Vinson Syndrome (PVS)<sup>1</sup>. It is also called Paterson Brown Kelly Syndrome<sup>1</sup>. Henry Plummer was the first to describe PVS in 1911 and Port Vinson in 1919.

Exact data about the incidence and prevalence of the disease is not available. In the first half of 20<sup>th</sup> century PVS was common in Caucasians, particularly in middle aged women<sup>2</sup>. The incidence of PVS is decreasing in the world because dietary inadequacy is becoming uncommon<sup>3</sup>. On the other hand the incidence of esophageal web formation and carcinoma of post-cricoid carcinoma is still common in Pakistan particularly in women of child bearing age due to a diet deficient in essential vitamins and minerals as well as environmental factors. Late treatment of menorrhagia due to social factors and lack of expertise are other important factors in Pakistan.

The patient presents with cervical dysphagia, upper esophageal webs and iron deficiency anemia. Most of the patients are in 4<sup>th</sup> to 7<sup>th</sup> decade of life. The syndrome has also been described in children and adolescents. Dysphagia is usually painless, intermittent and progressive over the years, more for solids and associated with weight loss. Symptoms associated with anemia like fatigue, weakness, pallor and tachycardia may also be present. Patient may have cheilitis, glossitis, and koilonychia<sup>3</sup>.

Esophageal web is about 2 to 3 mm wide. It is a smooth extension of normal esophageal tissue containing just mucosa and submucosa and can occur anywhere along the esophagus but classically at the anterior portion of postcricoid area of upper esophagus<sup>4</sup>.

It can be detected on barium swallow examination. Sometimes it may be an incidental finding<sup>5</sup>. Plummer Vinson Syndrome has a definite relationship with development of squamous cell carcinoma of upper gastrointestinal tract. Incidence of development of carcinoma is about 15%.<sup>6-8</sup> Endoscopic

dilatation is supposed to be a safe and cost effective method of treatment for esophageal webs and strictures with a low complication rate.<sup>6</sup> The purpose of the study was to confirm this.

### Patients and Methods

The study was conducted in the department of Otorhinolaryngology Rawalpindi General Hospital, Rawalpindi. A total of 25 patients diagnosed with Plummer Vinson Syndrome who presented in our department from July 2005 to June 2007 were included. 23 patients had dysphagia for solids only while 2 female patients had dysphagia for solids as well as liquids. Mean duration of dysphagia was 18 months. These patients were refractory to conservative treatment. 2 female patients had history of *hukka* and *niswar* addiction. Thorough history, clinical examination and relevant examination were carried out which included blood complete examination, serum iron levels and barium swallow examination. 3 patients were male and 22 were females. None of the patients was suffering from recent upper respiratory tract infections, hypertension, diabetes mellitus or asthma. All patients had clinically proven iron deficiency anemia and web formation in upper part of esophagus. All the patients were examined clinically. Complete ear, nose and throat examination was done. Indirect laryngoscopy was done in all patients. Patients were admitted in the ward one day prior to surgery. Pre operatively they were investigated for fitness of anesthesia.

These 25 patients underwent esophagoscopy and biopsy. 23 patients had normal esophageal mucosa on biopsy and 2 patients had carcinoma of hypopharynx. These 2 patients were excluded from the study.

**Table 1: Pre-op estimate of dysphagia**

Degree of dysphagia	No. of patients (n=23)	Percentage
---------------------	------------------------	------------

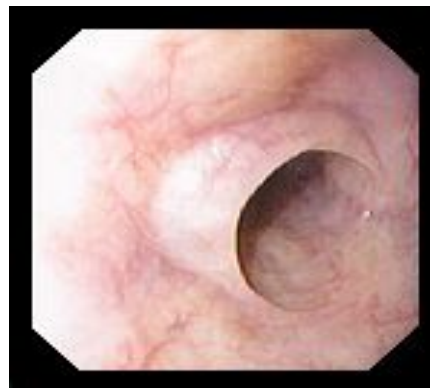
No difficulty	00	00
Mild difficulty in swallowing	05	22
Swallowing with effort	08	35
Swallowing for liquids only	10	43
Total patients	23	100

Esophagoscopy was done under general anesthesia. Adult size esophagoscope was used. Hypopharynx and esophagus were examined completely after taking all the precautionary measures. Findings were noted (Figs 1-4). Web was completely excised and dilated in 23 patients with the help of gum elastic bougies and adult sized esophagoscope. Post operatively patients were started orally on Ferrous fumarate 300mg and Folic acid 5 mg one tablet daily for 3 months. Patient follow up was done after one month, two months, six months and one year.

Pre and post operatively patients were assessed for dysphagia for solids and liquids. The dysphagia was classified as follows. 0 = No difficulty in swallowing, 1 = Mild difficulty in swallowing; 2 = swallowing with more effort; 3 = swallowing for liquids only.(Table1).

### Results

Out of 23 patients who underwent esophagoscopy and dilatation, 21 were females and 2 were males. Female to male ratio was 10:1. The age of the patients ranged from 35 to 66 years. The main presenting symptom was dysphagia for solids.



**Fig 1: Esophageal web on endoscopy**

Of the total 25 biopsies, normal esophageal mucosa was diagnosed in 23 while squamous cell carcinoma was found in two patients giving incidence of carcinoma as 8%. After esophageal dilatation 20 (87%) patients had no difficulty in swallowing six months after dilatation (Table 2). In 2 patients there was mild dysphagia after 3 months of follow up. Second dilatation was done in these two patients. These patients then became symptom free and no web was seen on subsequent barium swallow x-ray.

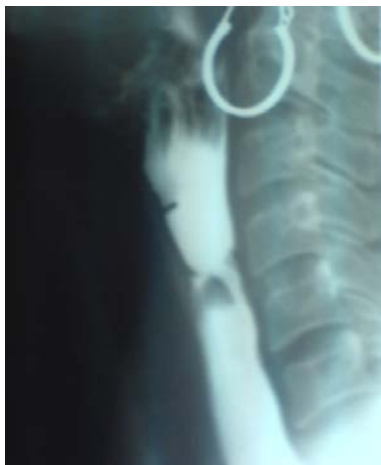

Fig 2: Esophageal web on barium swallow

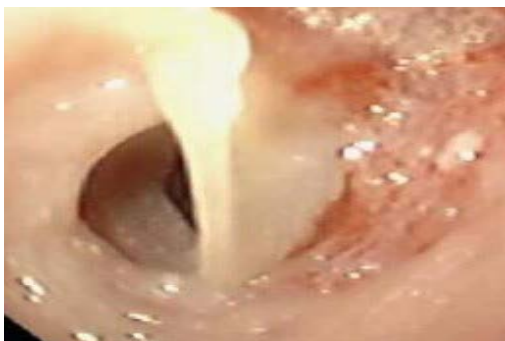
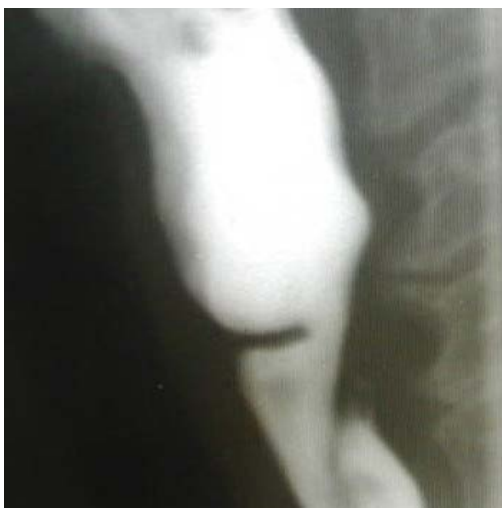
Fig 3: Endoscopic view of esophageal web



### Fig 4: Esophageal web on x-ray Discussion

In the past Plummer Vinson Syndrome was common in the Scandinavian population, especially in rural areas of Sweden but nowadays it is rare over there<sup>3</sup>. It is still common in developing and under developed countries. In the world incidence of the disease is decreasing. This is because of better nutrition. However it is still high in Pakistan especially in females of child bearing age because of a diet deficient in essential vitamins and minerals plus late diagnosis and treatment of menorrhagia.

Table 2: Estimate of dysphagia after surgery

Degree of dysphagia	No. of patients (n=23)	Percentage (%)
No difficulty	20	87
Mild difficulty in swallowing	02	09
Swallowing with effort	01	04
Swallowing for liquids only	00	00
<b>Total patients</b>	<b>23</b>	<b>100</b>

In our study the average age of the patients was 50.5 years. In a study done by Novacek in 2005, most of the patients were middle aged women in fourth to seventh decade of life<sup>3</sup>. Plummer Vinson Syndrome was found to be a risk factor for developing squamous cell carcinoma of upper gastrointestinal tract. 15% of patients developed esophageal or pharyngeal cancer<sup>3</sup>. In our study 2 (08%) patients developed squamous cell carcinoma of hypopharynx.

A double membrane was detected in cervical esophagus in one of our patients. After esophagoscopy

and dilatation this patient also became free of dysphagia upto one year of follow up. A similar case was studied by Castro et al., in which a 27 year old patient had Plummer Vinson Syndrome. On endoscopic study a double membrane was detected in the cervical esophagus. After esophageal dilatation dysphagia disappeared and he remained asymptomatic.<sup>11</sup>

All our 23 patients were symptom free after 1 year of follow up. In a study done by Demirci et al., it was seen that most common benign cause of cervical dysphagia was esophageal web. (These webs are found in 5-15% of patients with dysphagia). Their two cases of Plummer Vinson Syndrome underwent esophagoscopy and dilatation of the webs Post operatively both patients were given oral iron therapy until their serum ferritin levels returned to normal level. Both patients were in good general health even after two years.<sup>9</sup>

In our study all patients post operatively received oral iron therapy and all were symptom free. This is in accordance with study done by Ned where a patient of 73 years of age presenting with dysphagia, a web in upper esophagus on esophagogastroscope and anemia was given oral iron therapy. Her symptoms completely disappeared.<sup>10</sup>

In our study a large percentage (87%) of patients were free of dysphagia six months after web dilatation while 2 (9%) had mild difficulty in swallowing. One (4%) patient had to swallow with effort. She underwent dilatation and curettage operation for some gynaecological problem. She again developed anemia, which resulted in reformation of web in upper esophagus. Her dysphagia was not completely relieved because of chronic anemia. No patient had difficulty in swallowing liquids only. 2 (9%) patients underwent re-endoscopy and re-dilatation.

All the patients were symptom free after one year of follow up.

## Conclusion

Esophagoscopy is a safe and cost-effective procedure. Plummer Vinson Syndrome if diagnosed earlier can be treated completely if we are able to maintain normal hemoglobin and iron levels. If untreated, it may lead to post-cricoid carcinoma which is a serious complication and difficult to treat. Use of tobacco, alcohol and *niswar* can be a contributory factor in developing carcinoma of upper gastrointestinal tract.

## References

1. Song LMWK: Plummer Vinson Syndrome: 2005 (7 June 2005); Available from URL: <<http://www.emedicine.com>>.
2. Wynder EL, Hultberg S, Jacobsson F, Bross IJ. Environmental factors in cancer of the upper alimentary tract. A Swedish study with special reference to Plummer Vinson (Paterson Kelly) syndrome. *Cancer* 1957;10:470-82.
3. Novacek G. Plummer Vinson Syndrome. Department of Internal Medicine IV, Division of Gastroenterology and Hepatology. Orphanet encyclopedia, July 2005.
4. Noshier JL Campbell WL, Seaman WB; The clinical significance of cervical esophageal and hypopharyngeal web; *Radiology*. 1975 Oct; 117(1):45-7. (abstract)
5. Wilson JA: The esophagus in Otolaryngology, Scott-Brown Otolaryngology and Head & Neck Surgery. Kerr. 6<sup>th</sup> ed. Oxford Butterworth-Heinemann, 1997; p24-25.
6. Alam A, Butt AK, Shafqat F, Endoscopic dilatation of esophageal strictures – An analysis of 54 patients. *Proceeding Shaikh Zayed Postgrad Med Inst* 2001;15(1):1-3.
7. Chisholm M. The association between webs, iron and post-cricoid carcinoma. *Postgrad Med J* 1974;50:215-19.
8. Messman H: Squamous cell cancer of the esophagus. *Best Pract Res Clin Gastroenterol* 2001;15:249-65.
9. Demirci. F, Savas MC Plummer Vinson Syndrome and dilation therapy: A report of two cases. *Turk J Gastroenterol* 2005; 16(4):224-27.
10. Ned TG. Severe deglutition disorders and iron deficiency. 1991 Nov 9;135(45):2136-37.
11. Castro M, Marques JL, Guerrero P, Castilla L, Guillen P. Double esophageal membrane in a patient with Plummer Vinson Syndrome. 1989 Jun;75(6):597-98.
12. Cecconello I, Felix VN, Zilberstein B, Machado MA, Volpe P, Pinotti HW. Cervical esophageal membrane and Plummer Vinson Syndrome. Report of a caseload and review of literature. 1994 Jul-Aug;(49)4:148-51.

